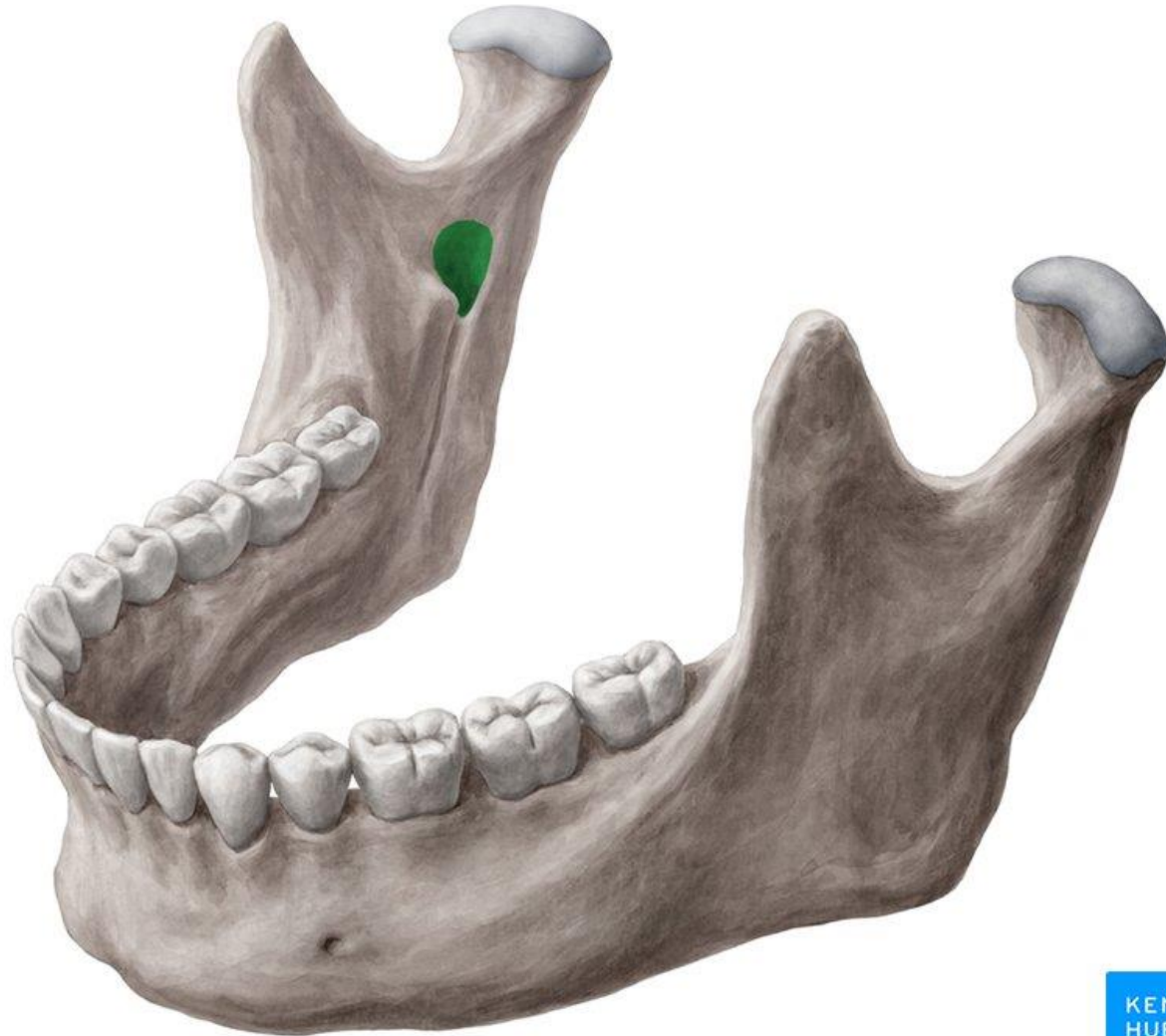
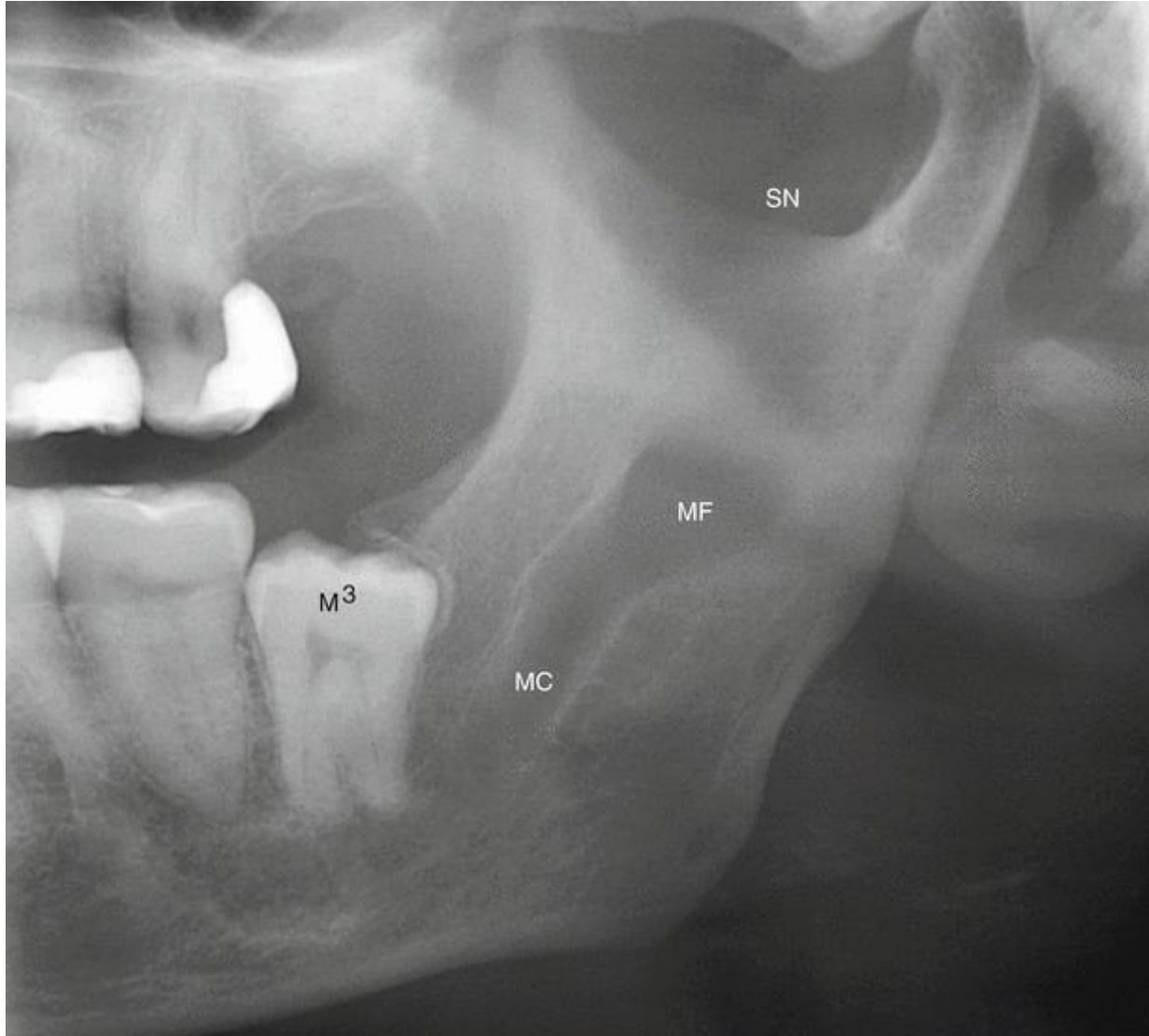


راديو لوسنسسى هاى فكين

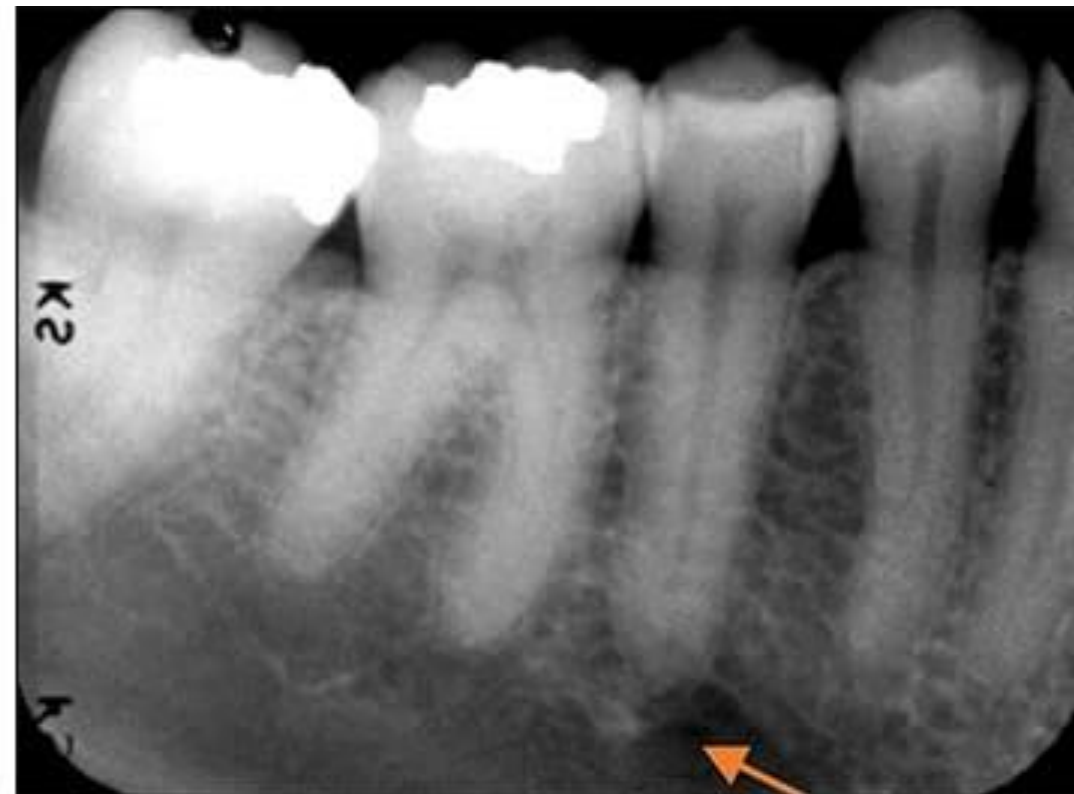رادىولوژى هاى آناتومىک

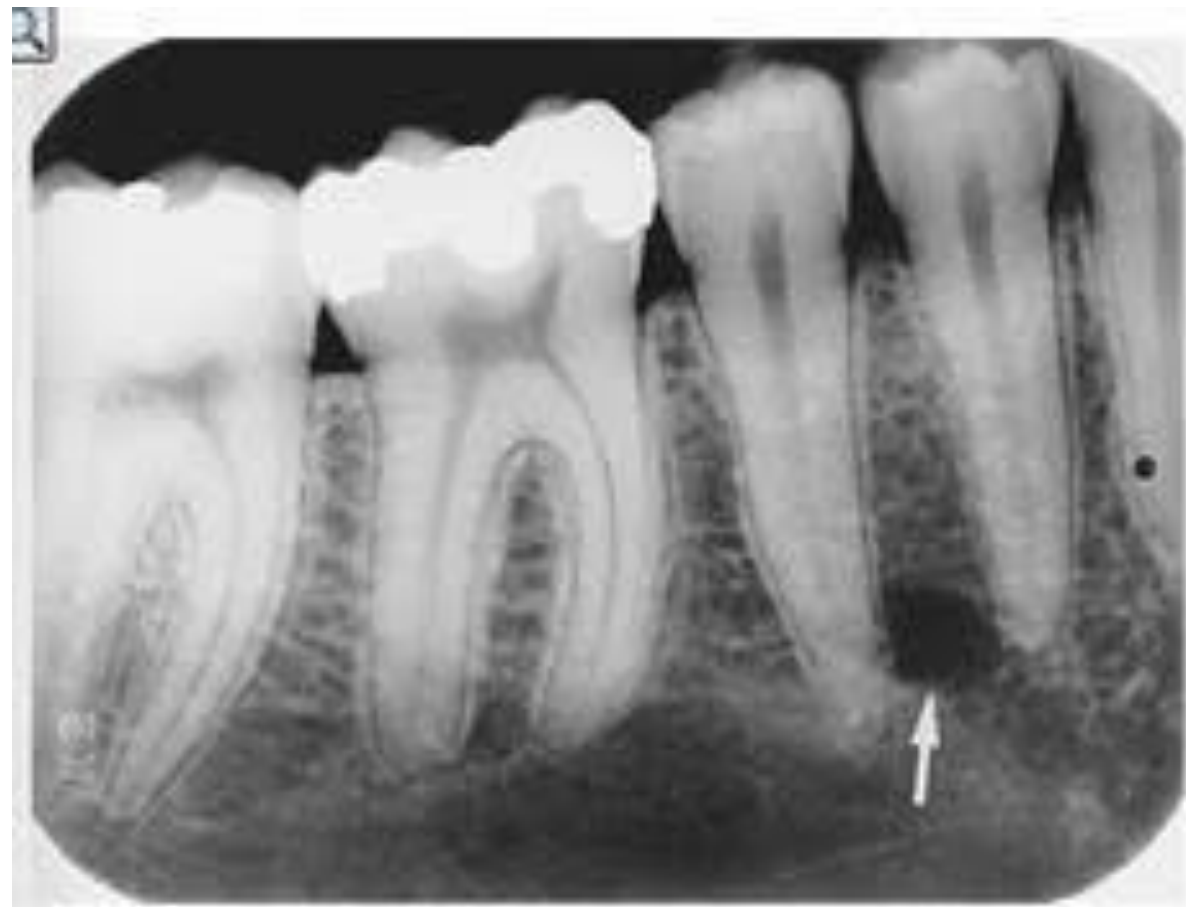فورامن منديبولار

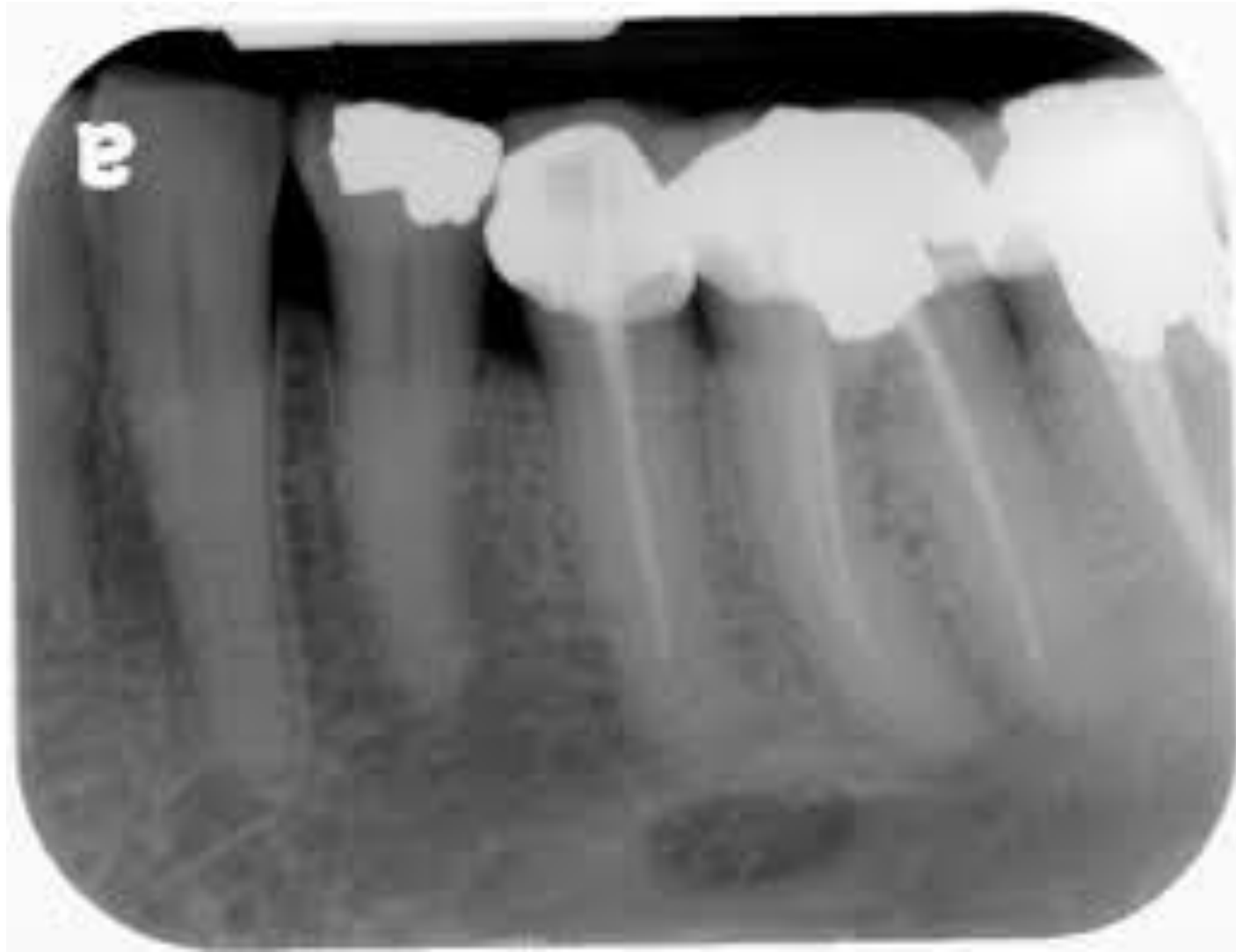



فورامن منتال

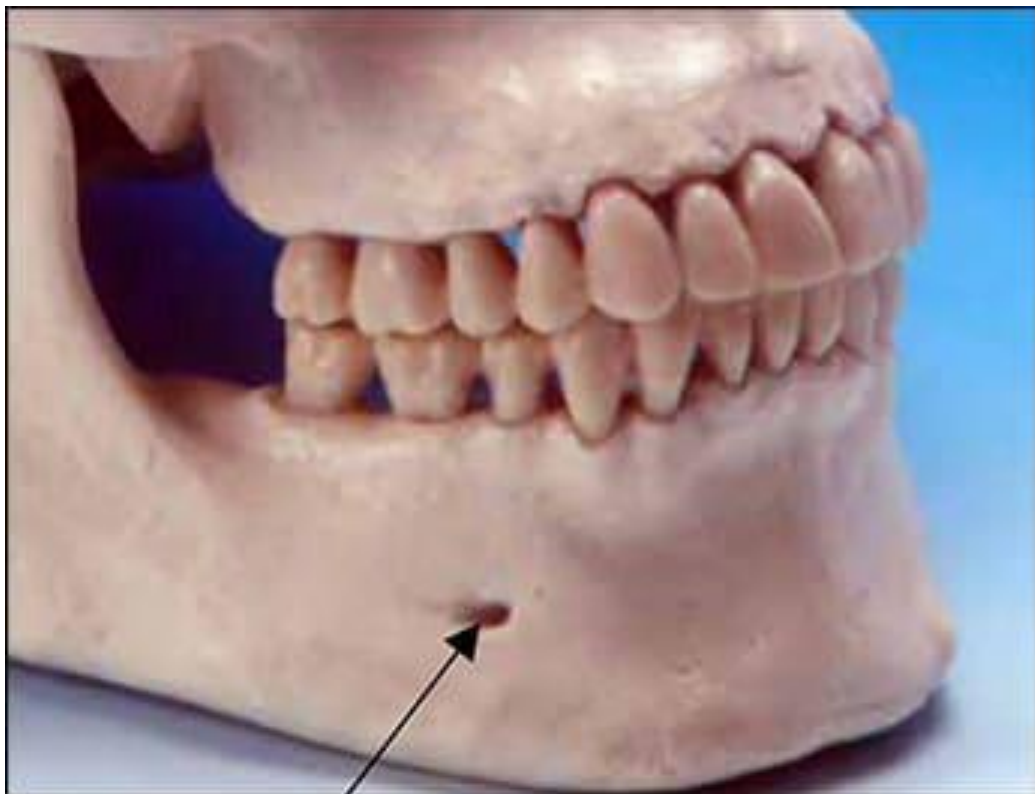




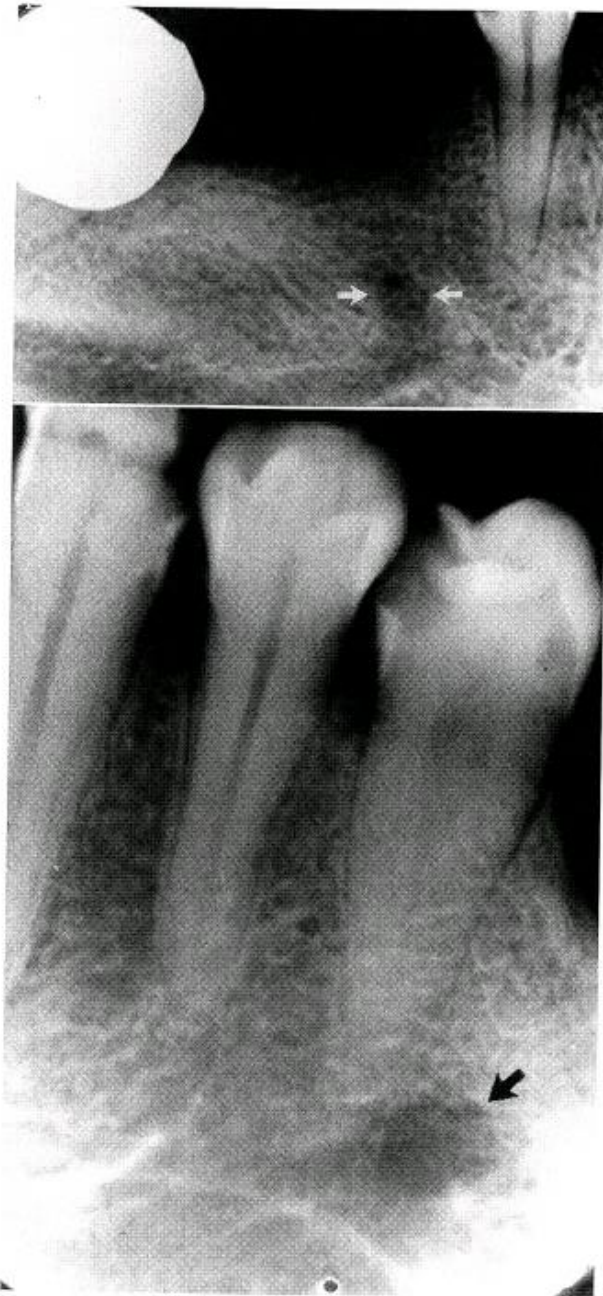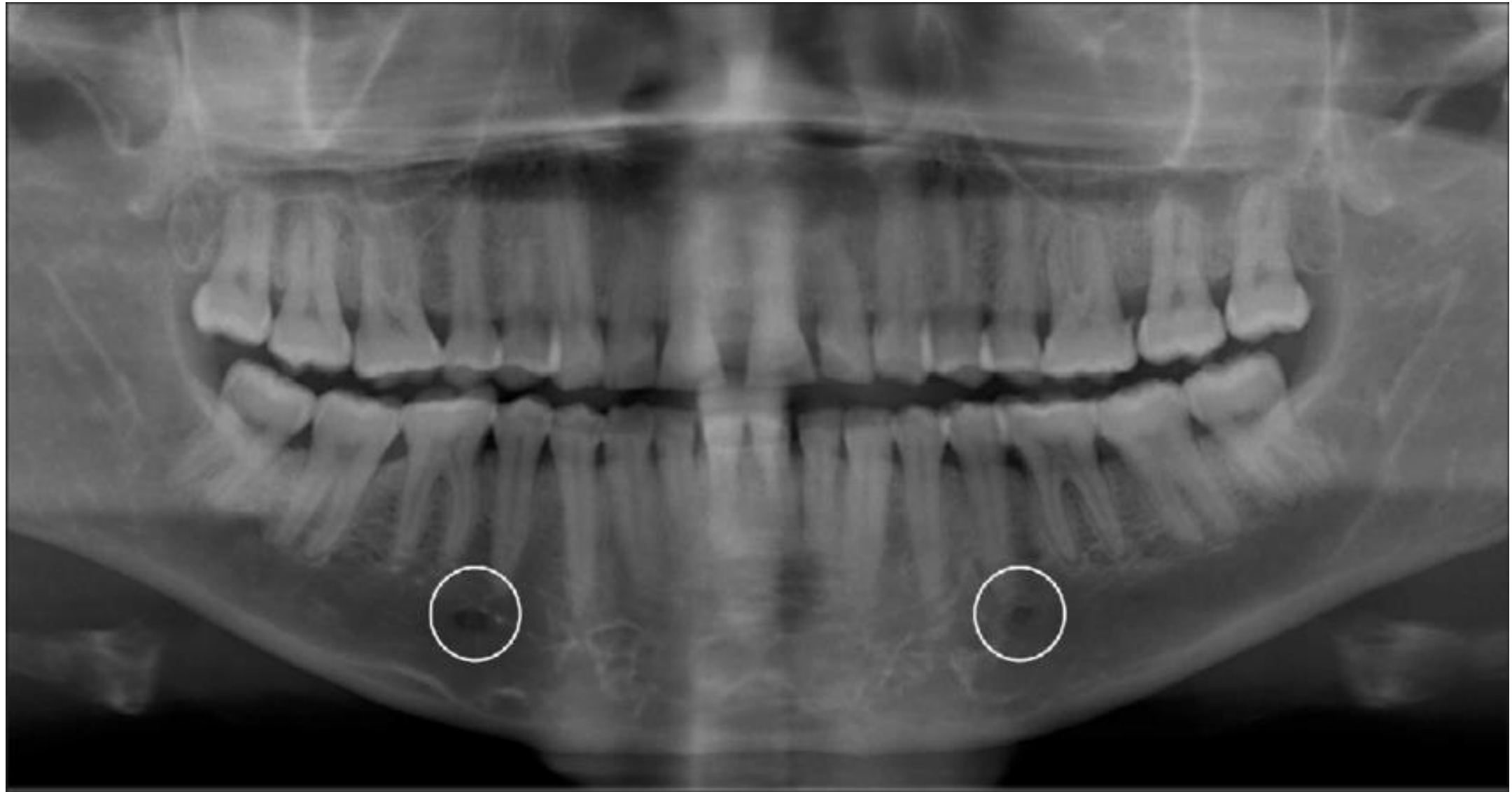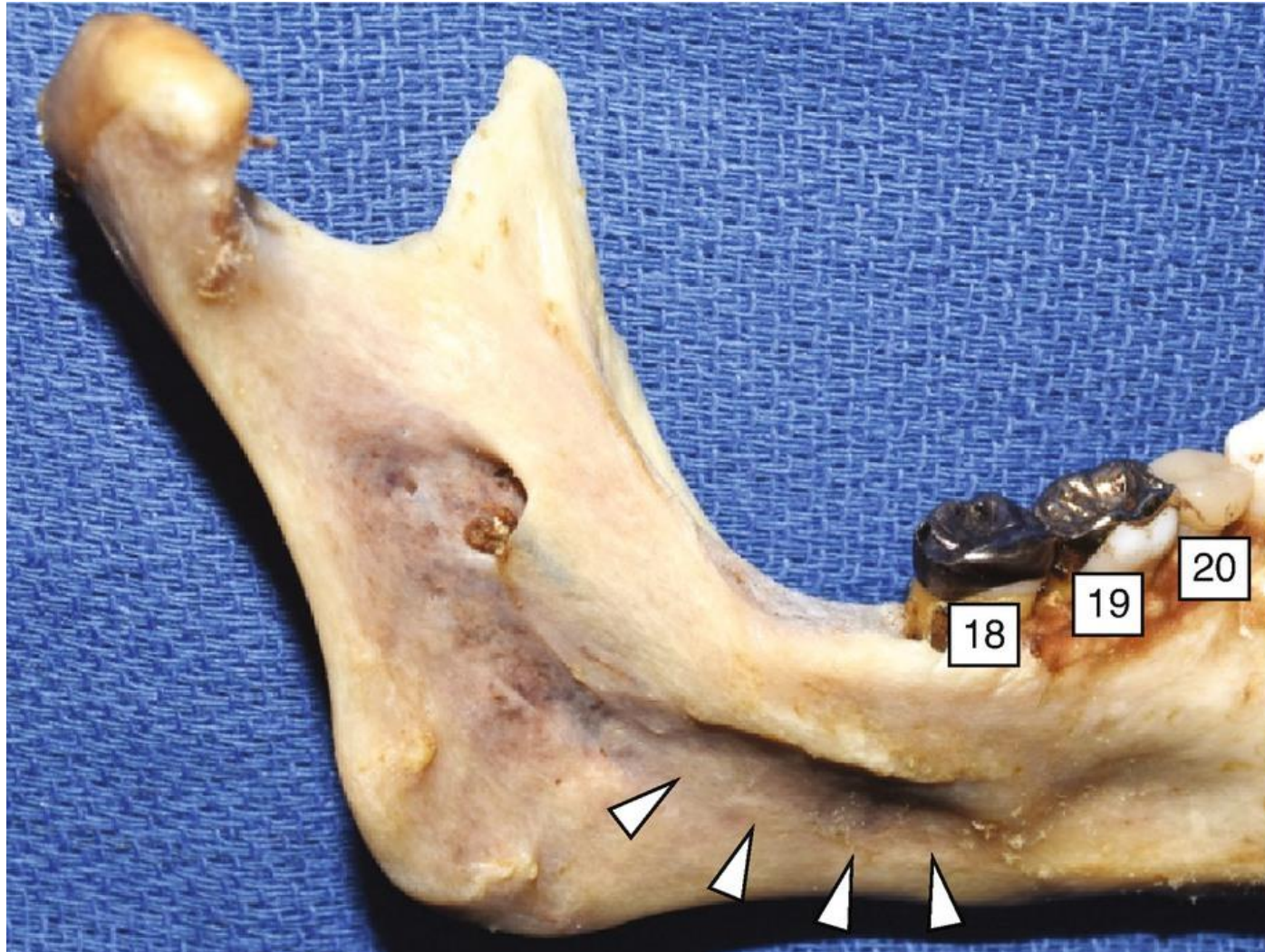


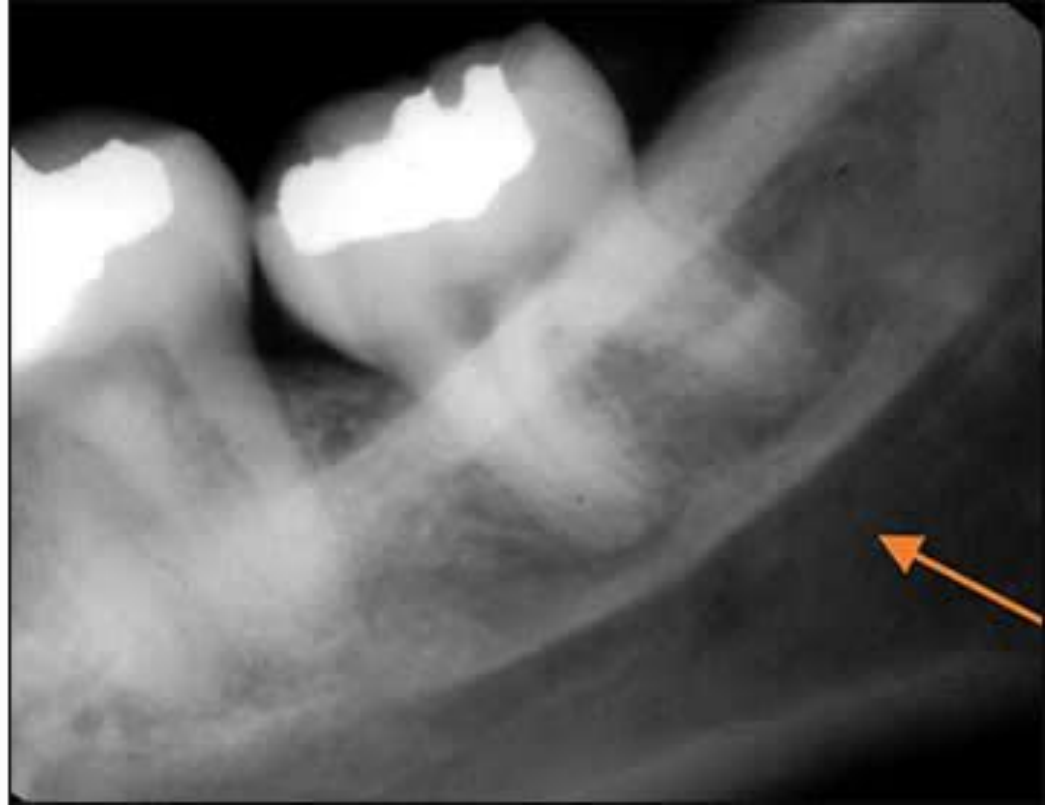
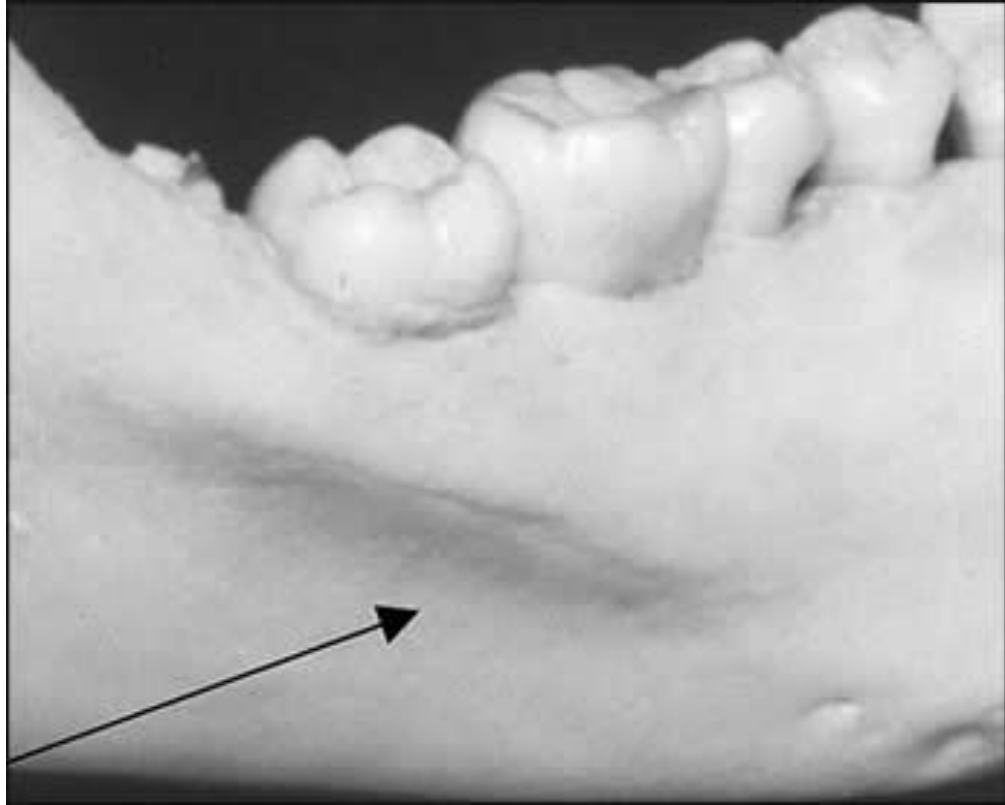


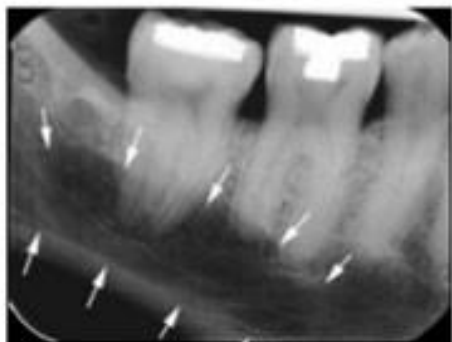
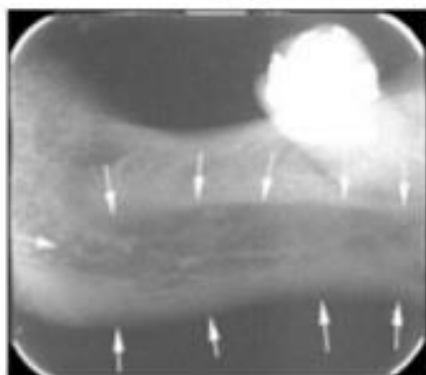
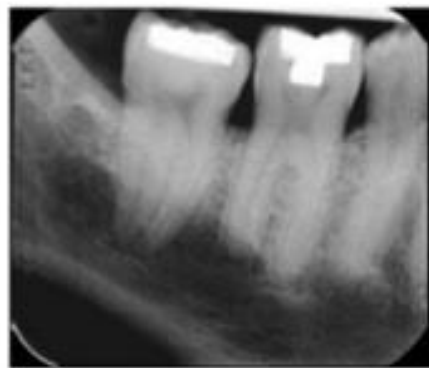
Fig. 15-4. A, Mental foramen (*arrows*). B, Mental foramen



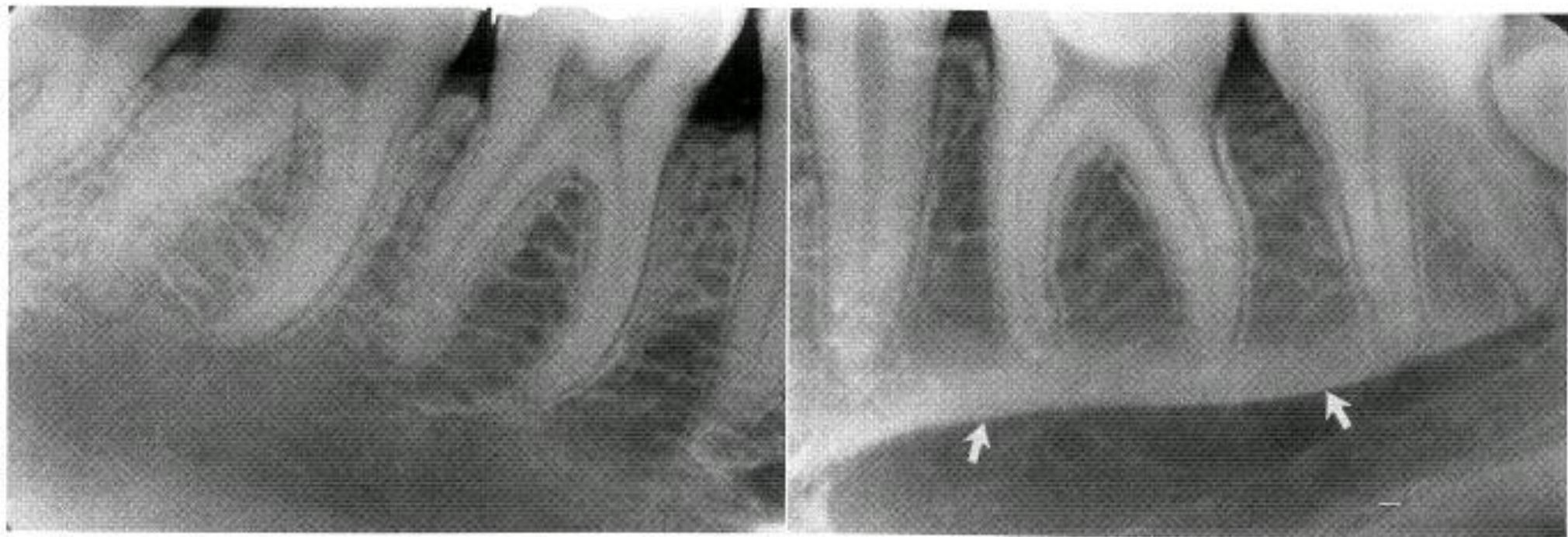
فوسای ساب مندیبولار



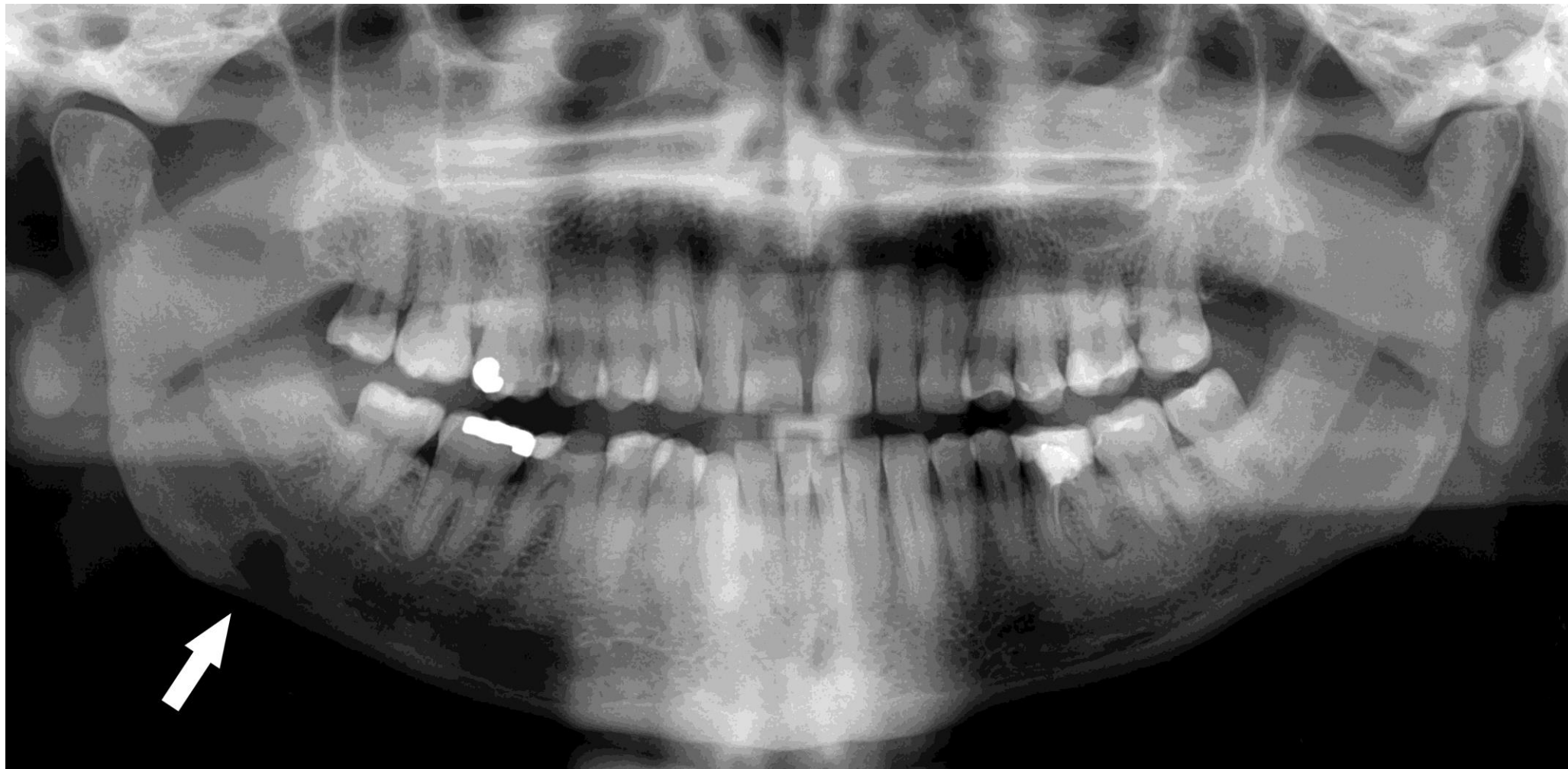


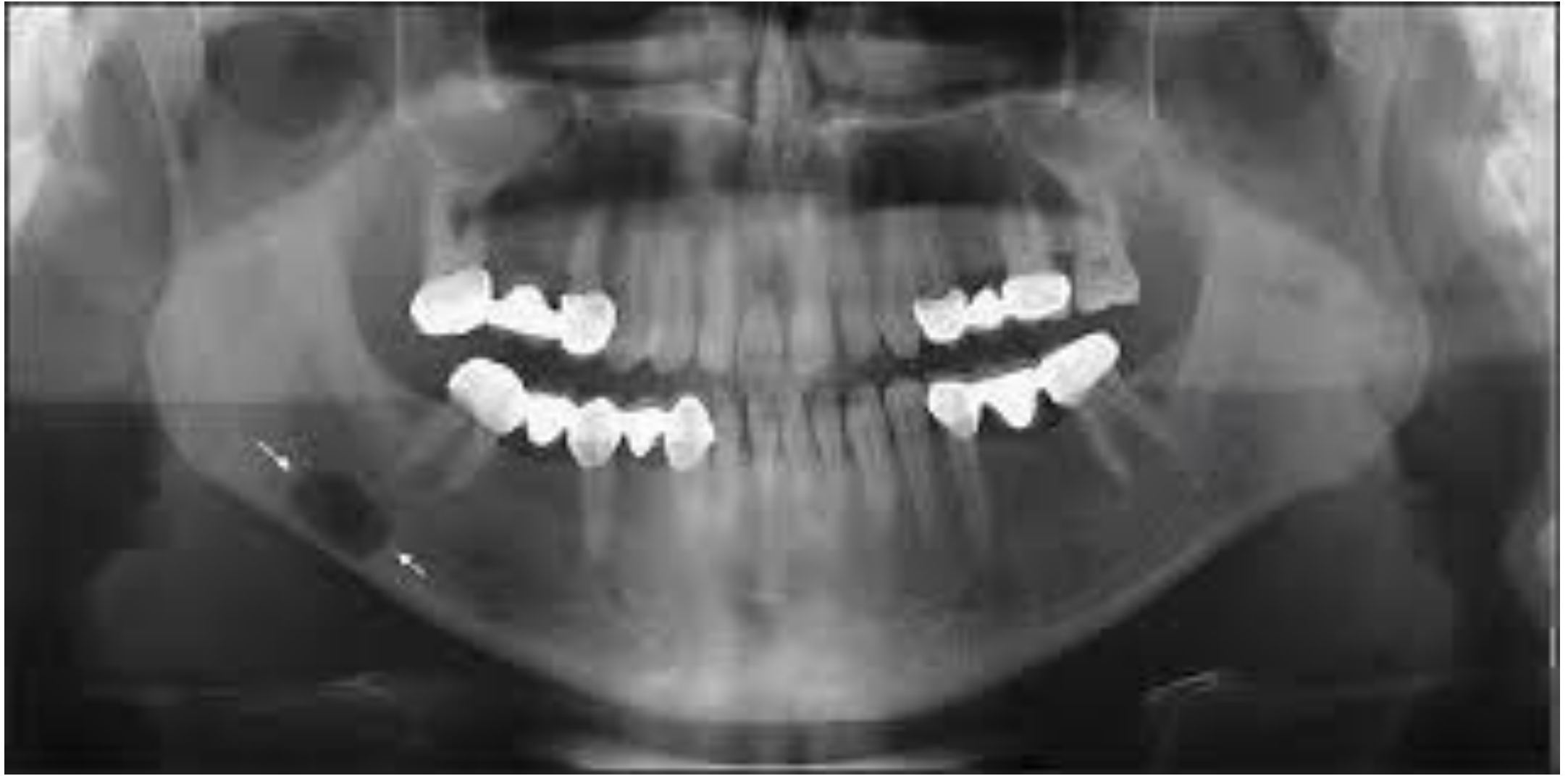
A

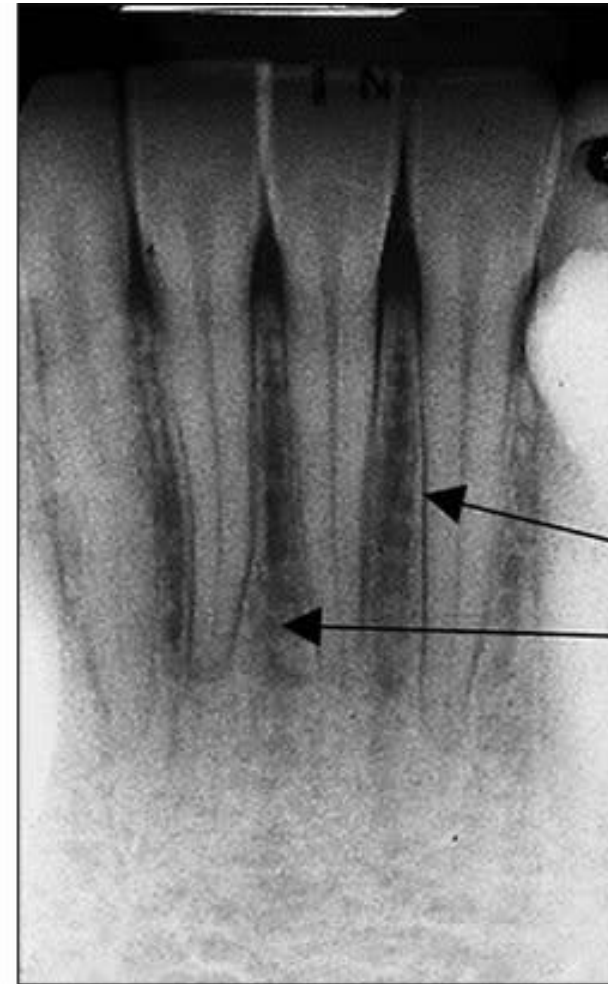
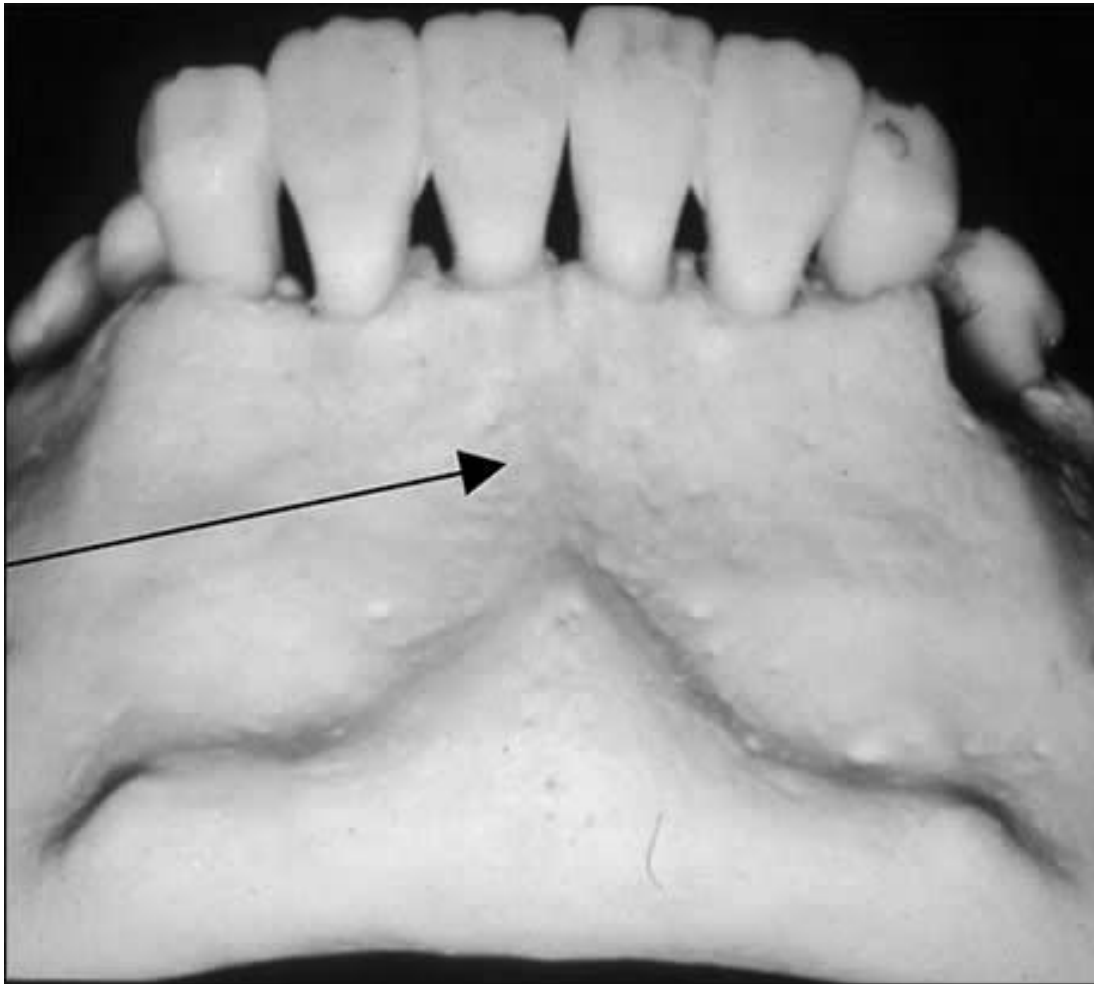


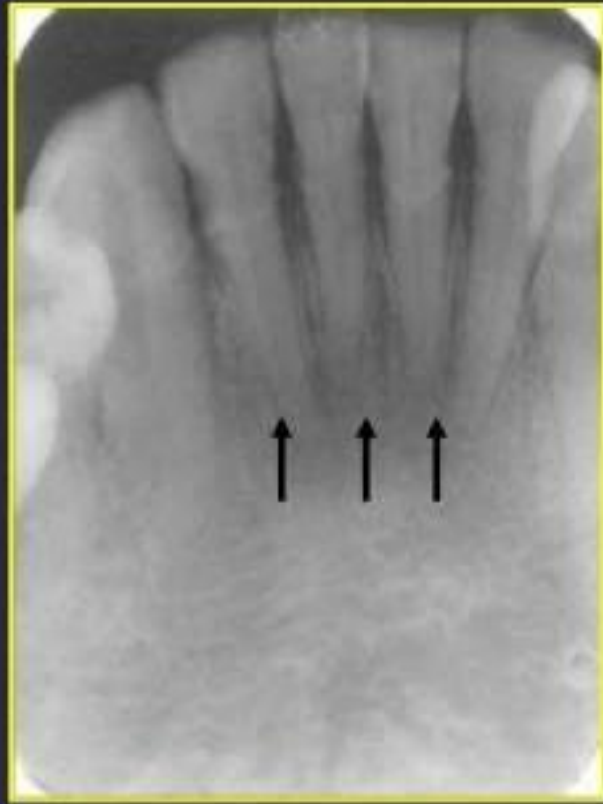
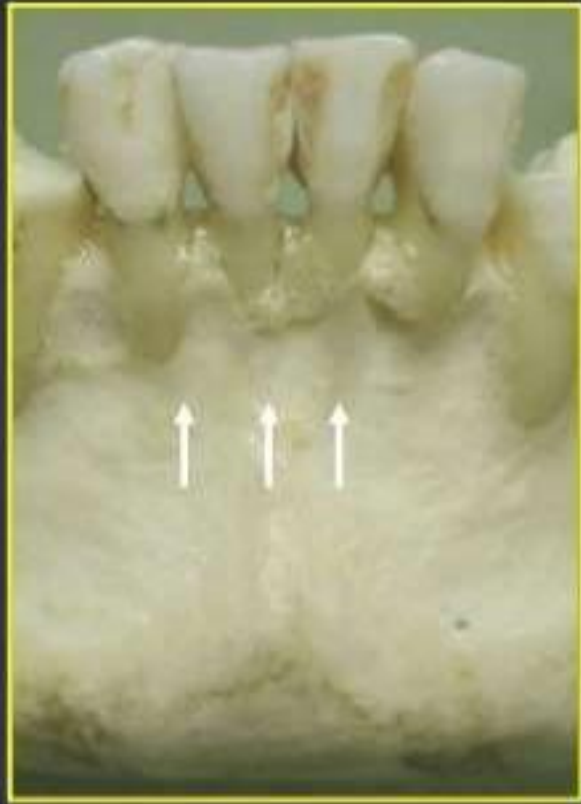سودو کیست استافنه



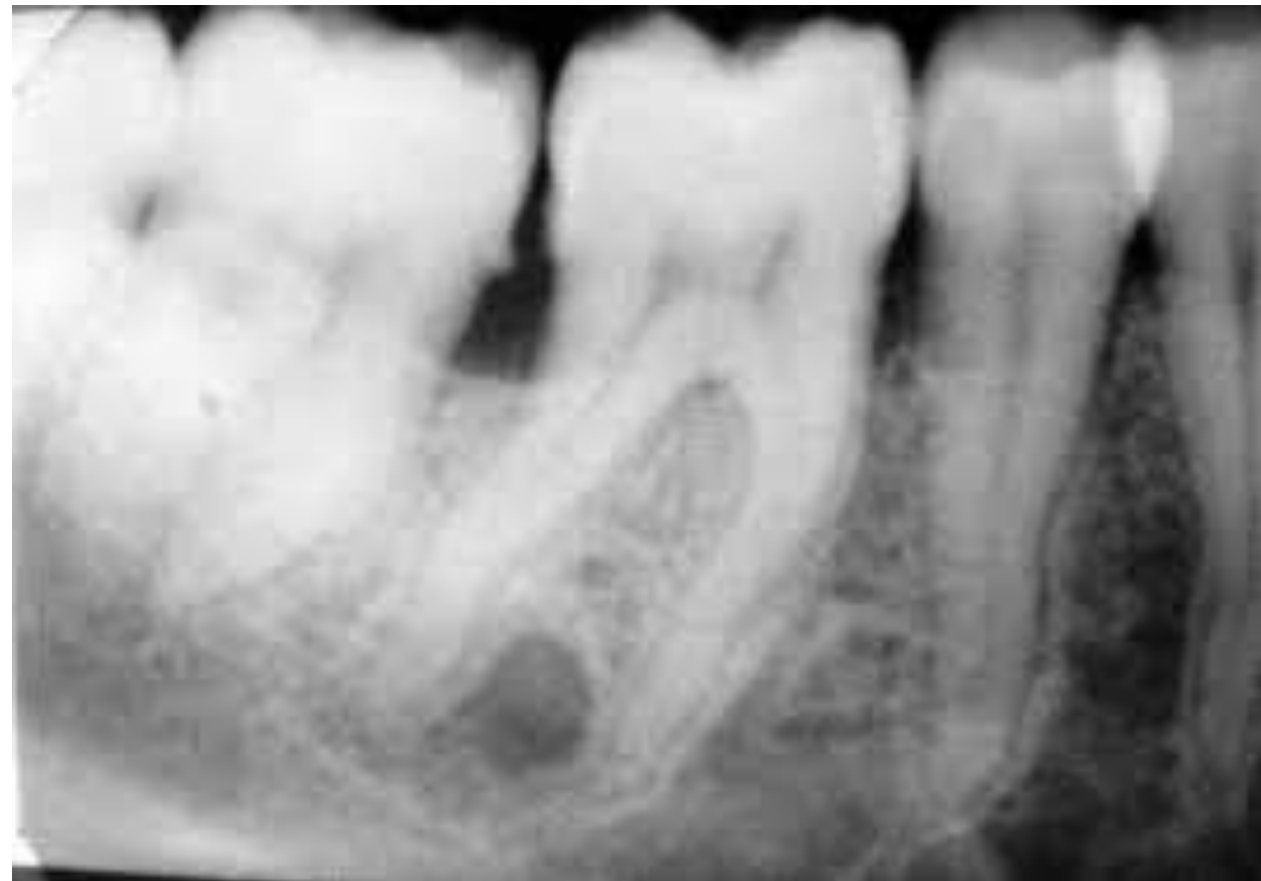
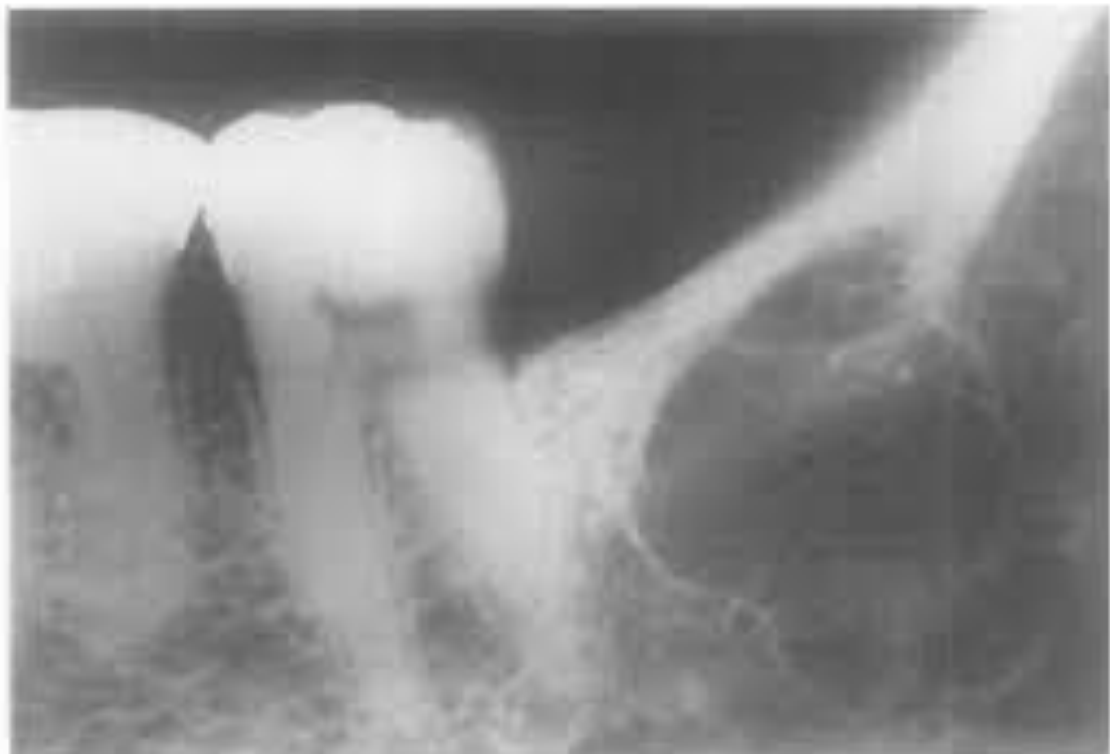
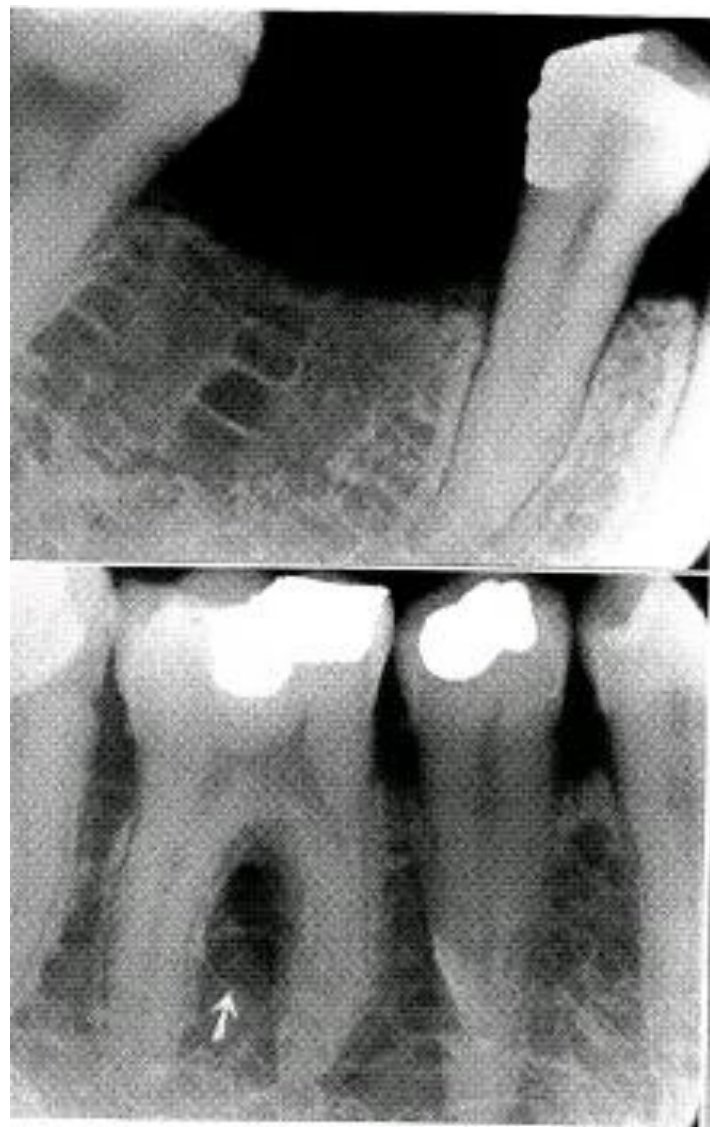
فوسای منتال



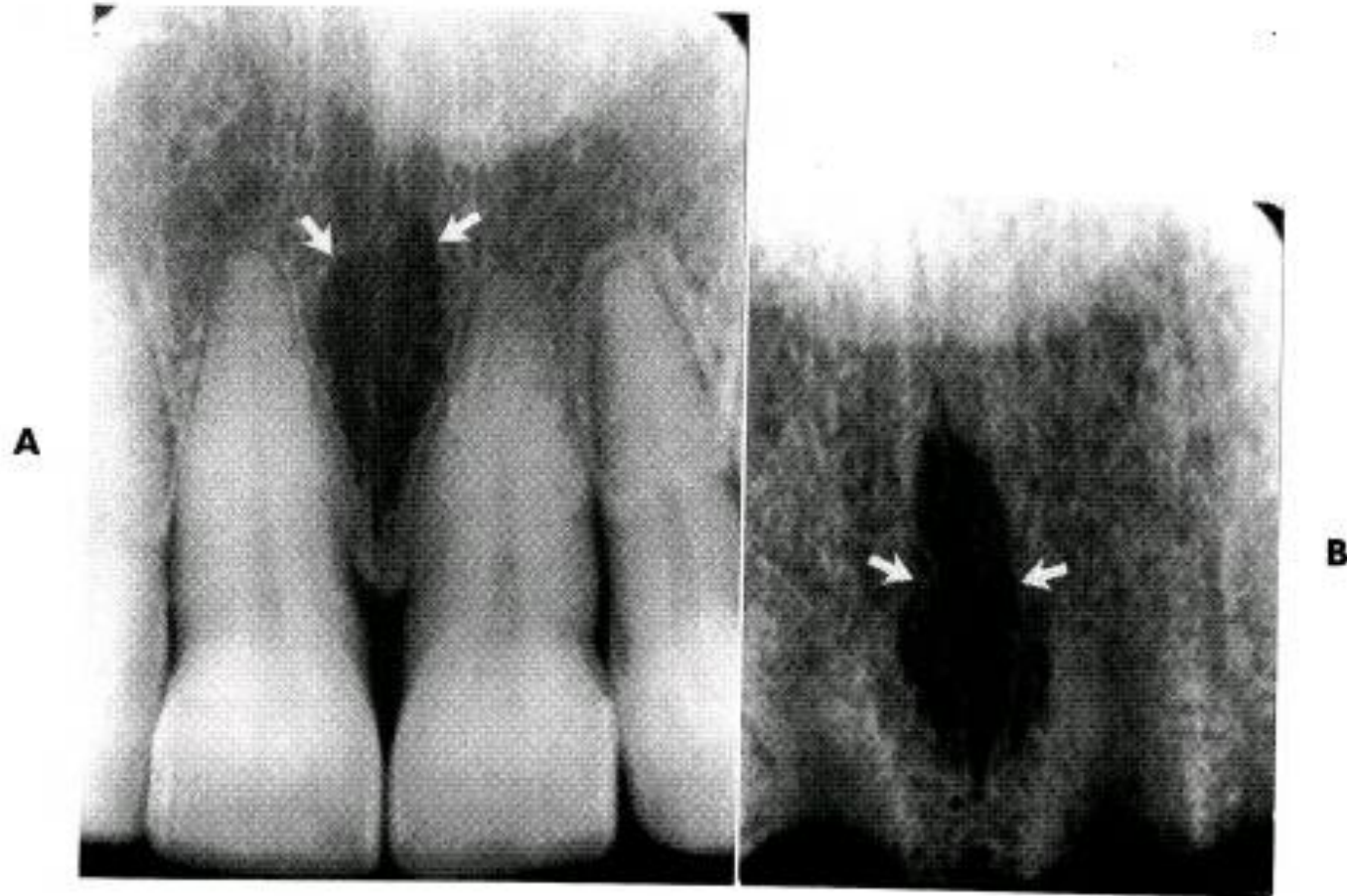

فضای مغز استخوان

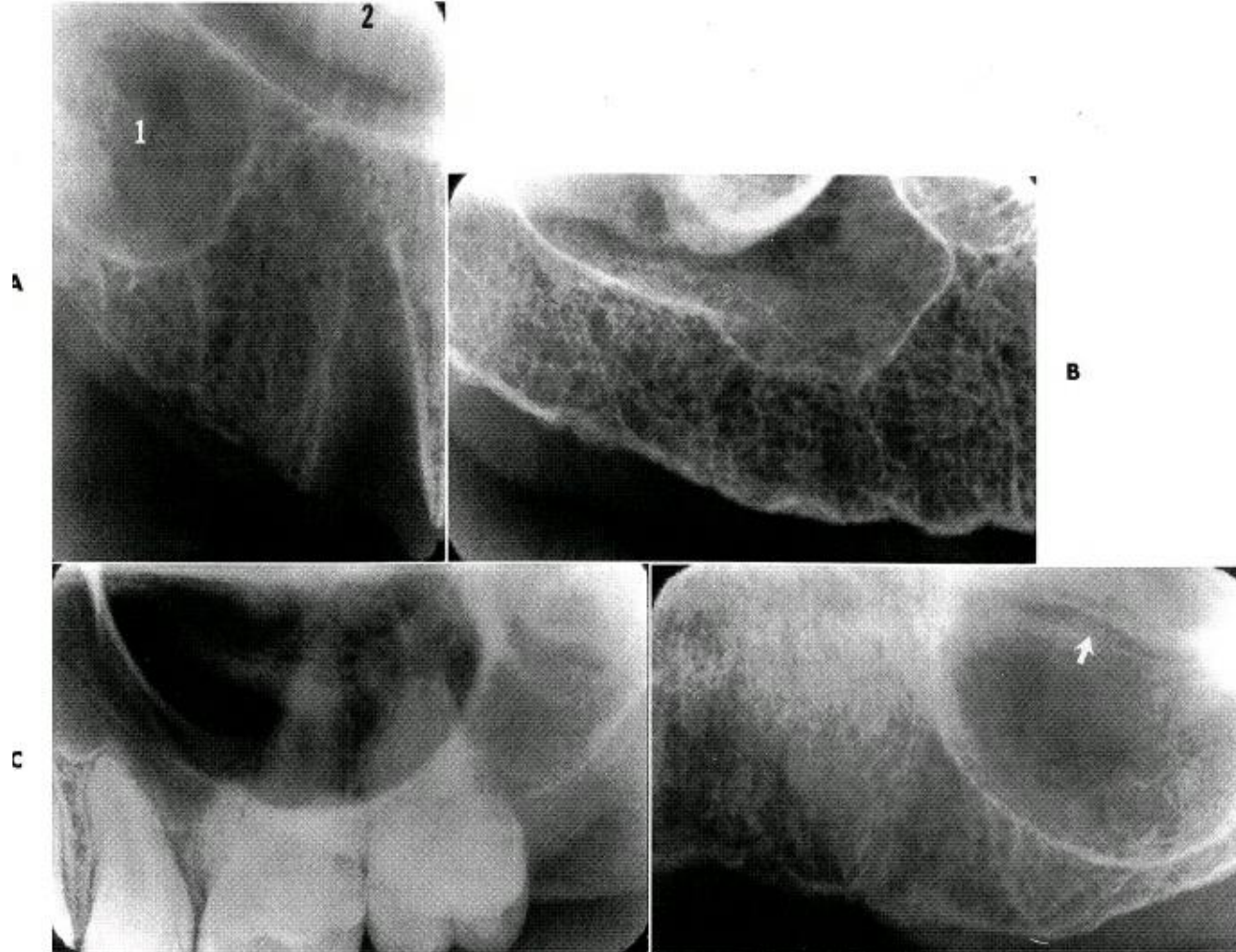




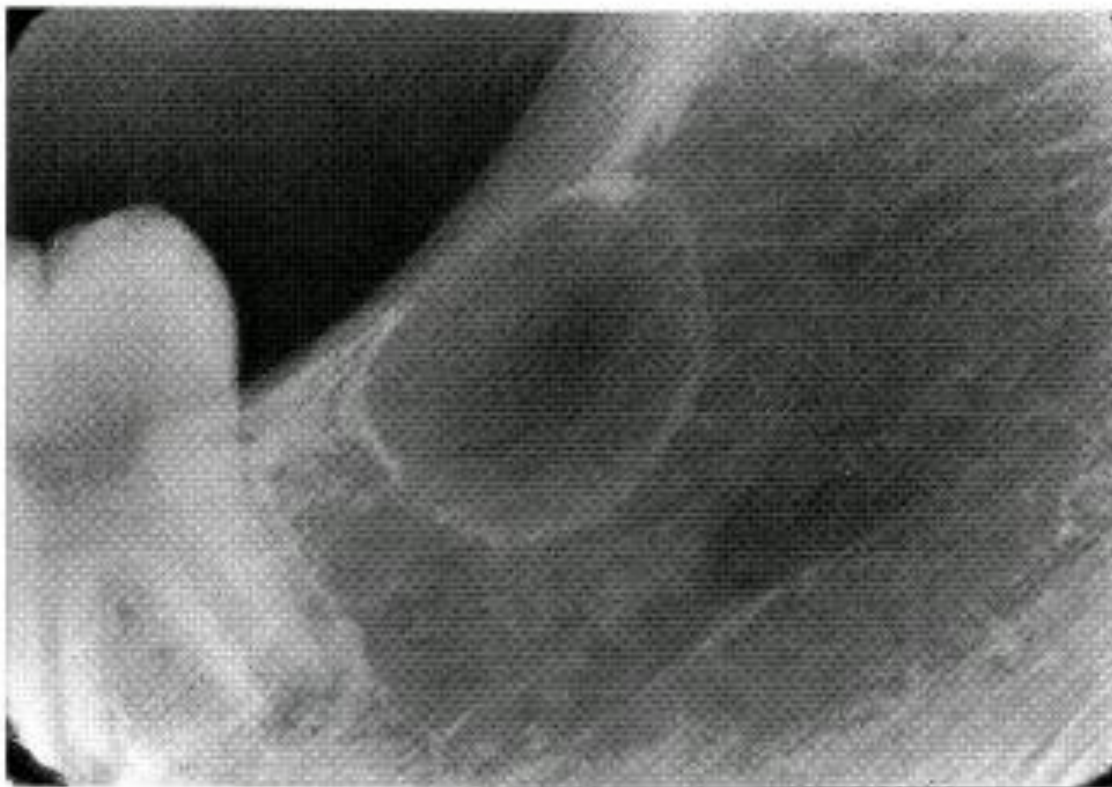
فورامن اینسیزیو



سينوس ماگزيلا

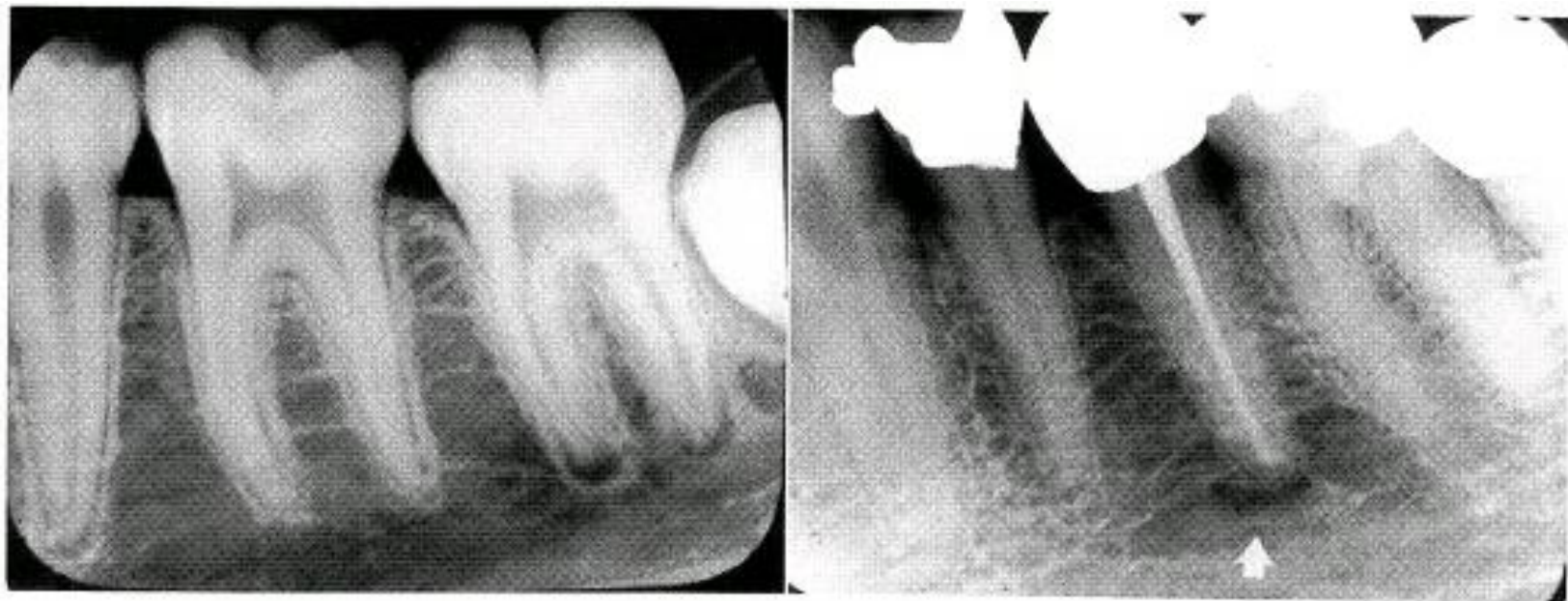


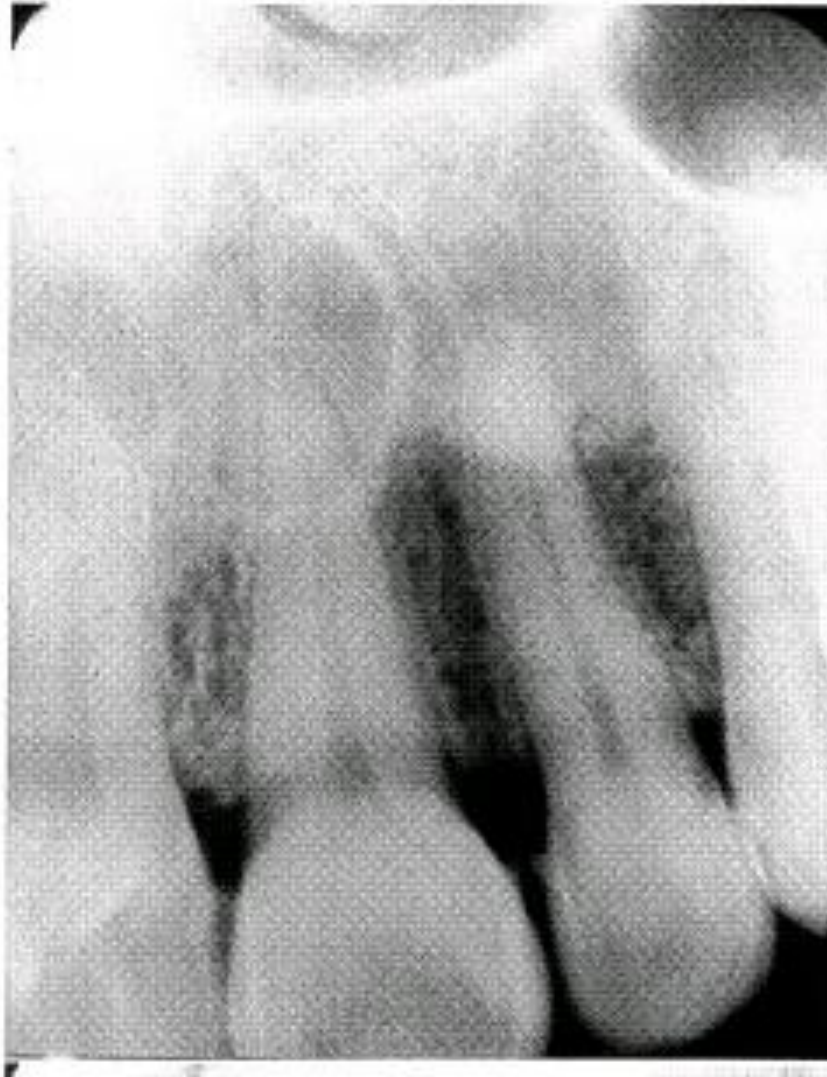کریپت دندانانی



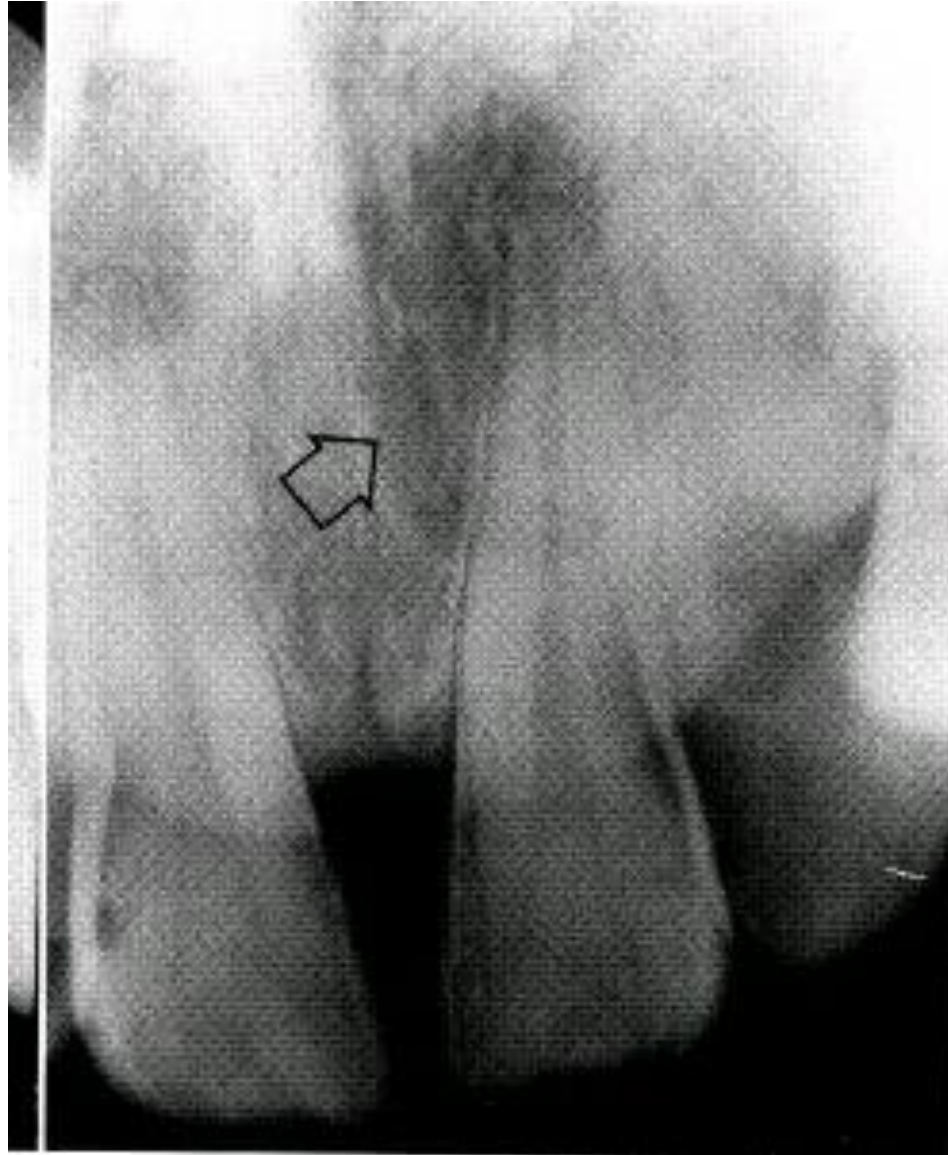
رادىولوژى هاى پرى اپىكال

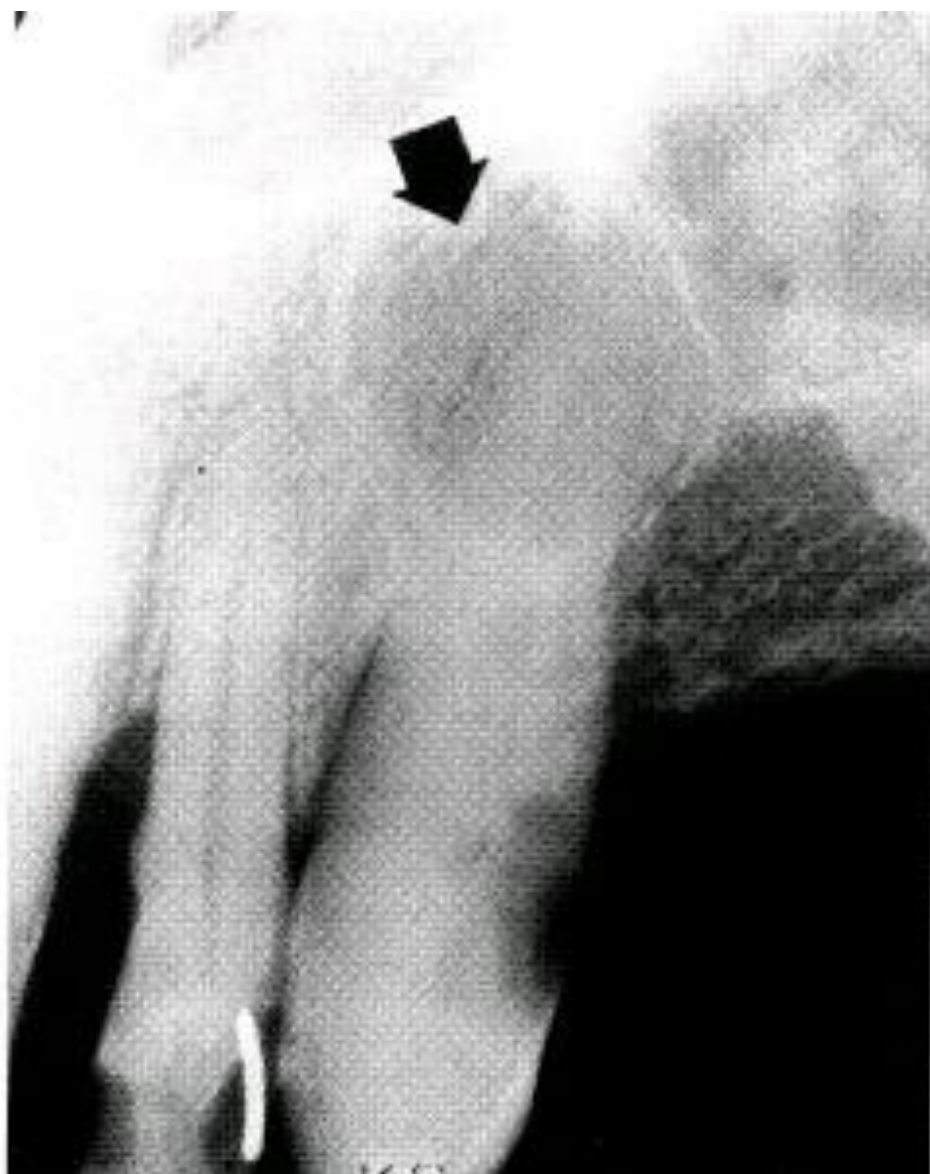
A



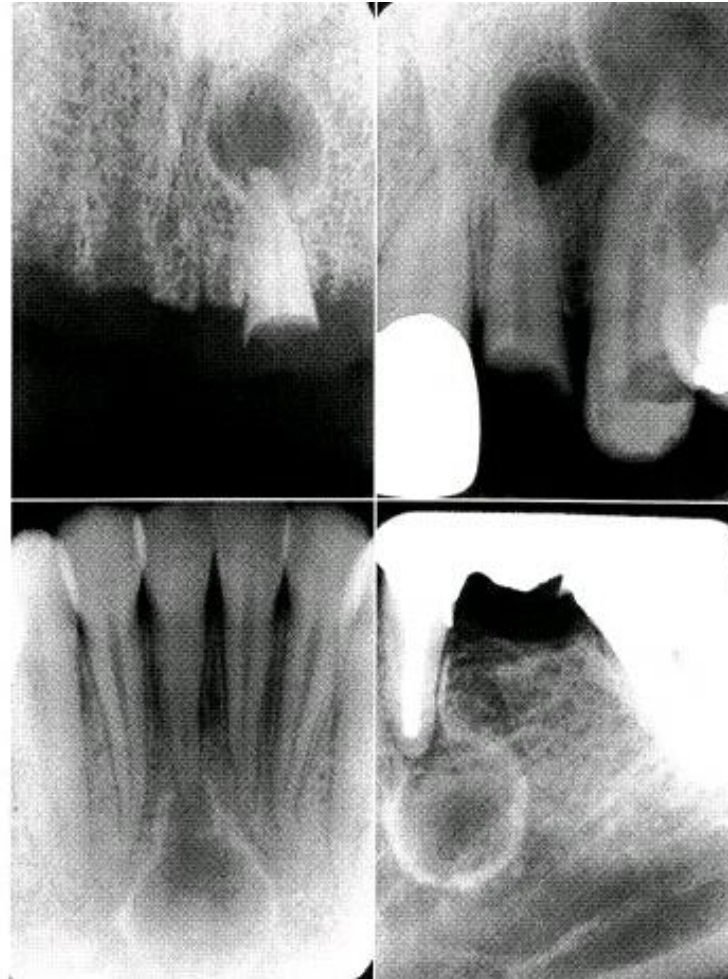

A

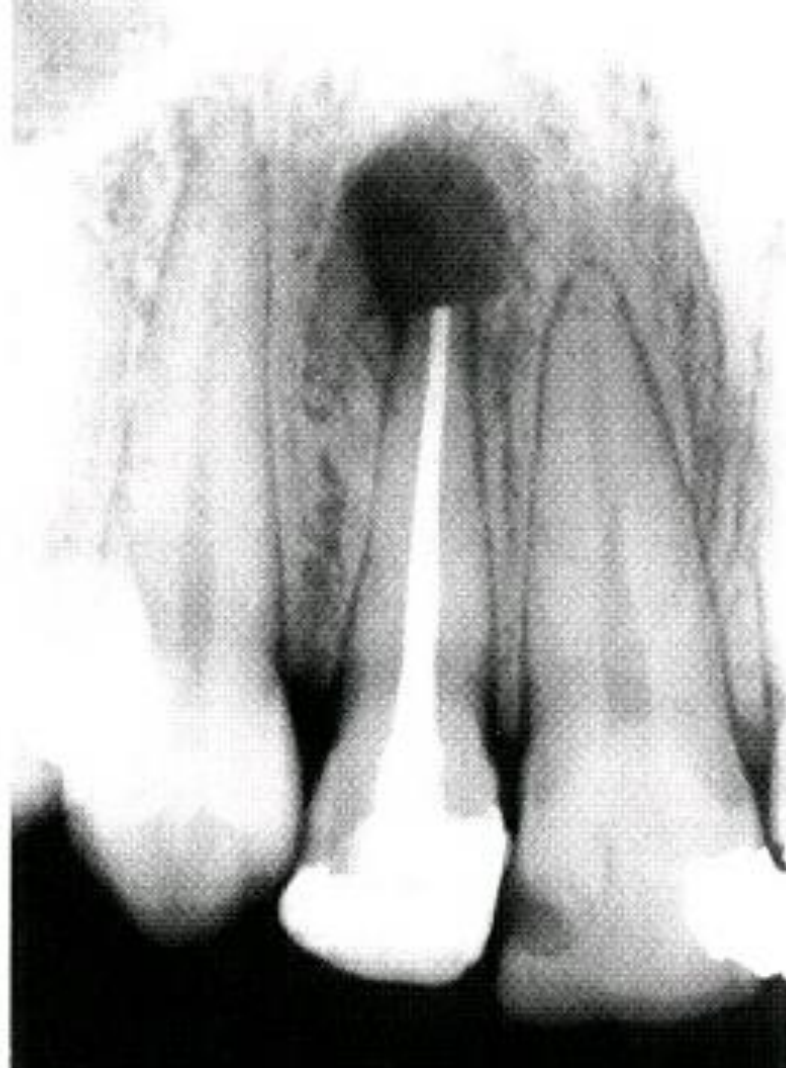




کیست رادیکولار



اسکار پری اپیکال



دیفکت جراحی

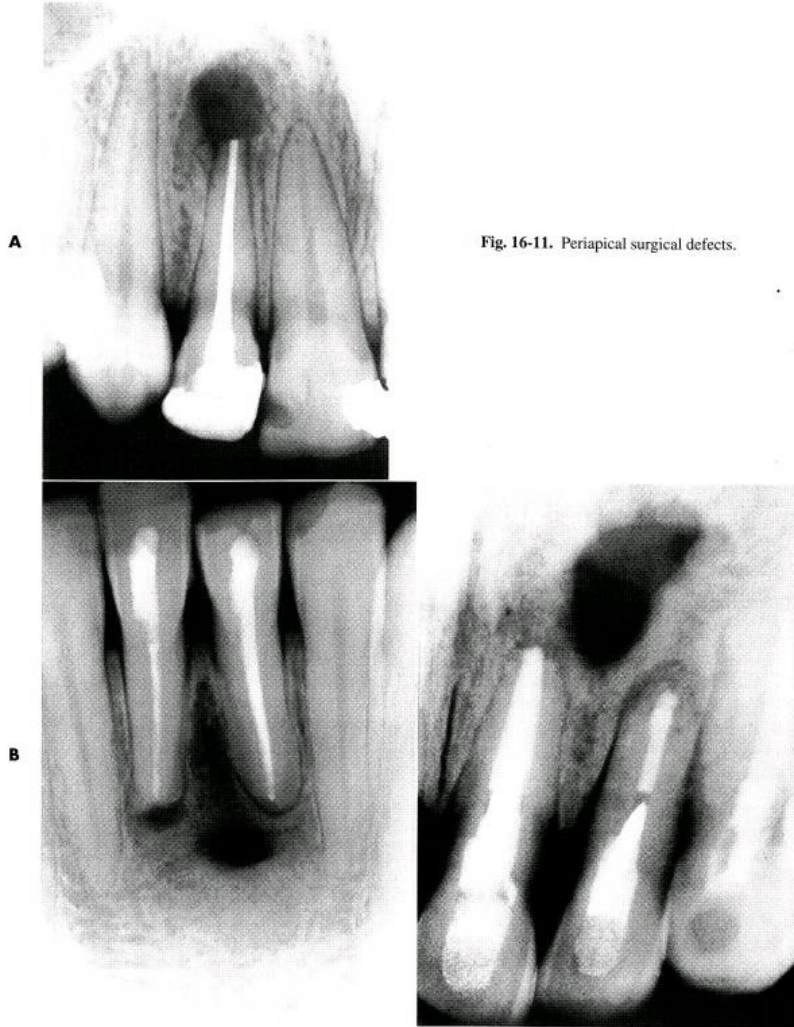
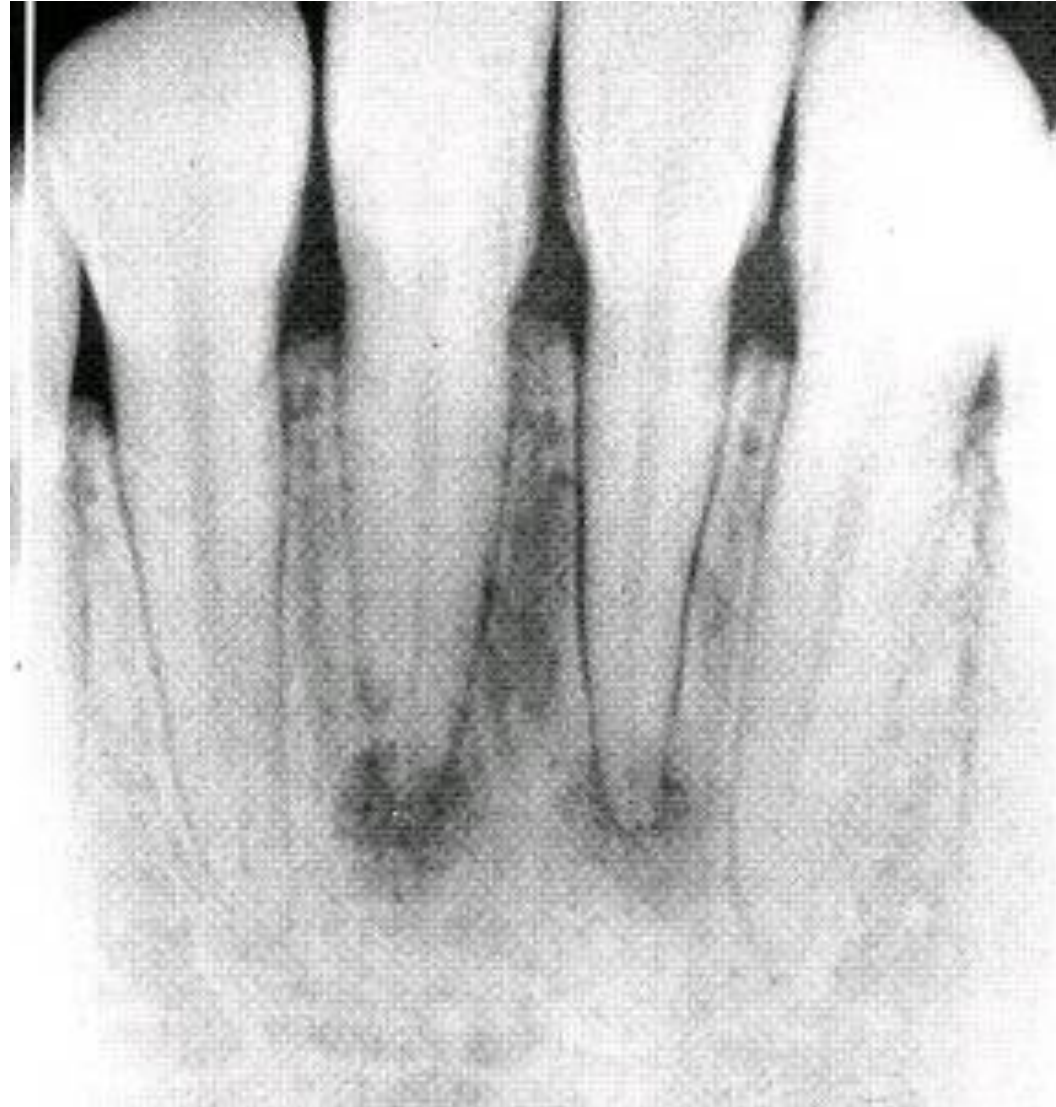

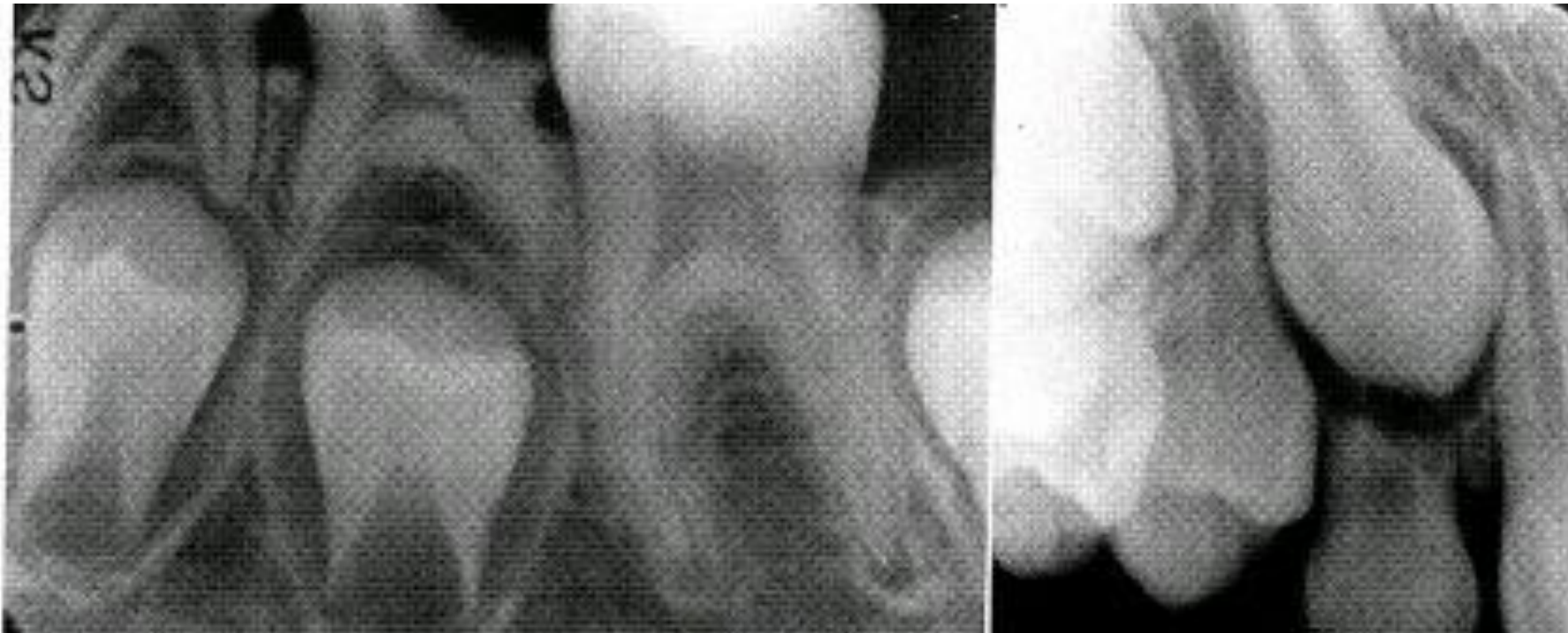Fig. 16-11. Periapical surgical defects.

ديسپلازی سمنتواسئوس

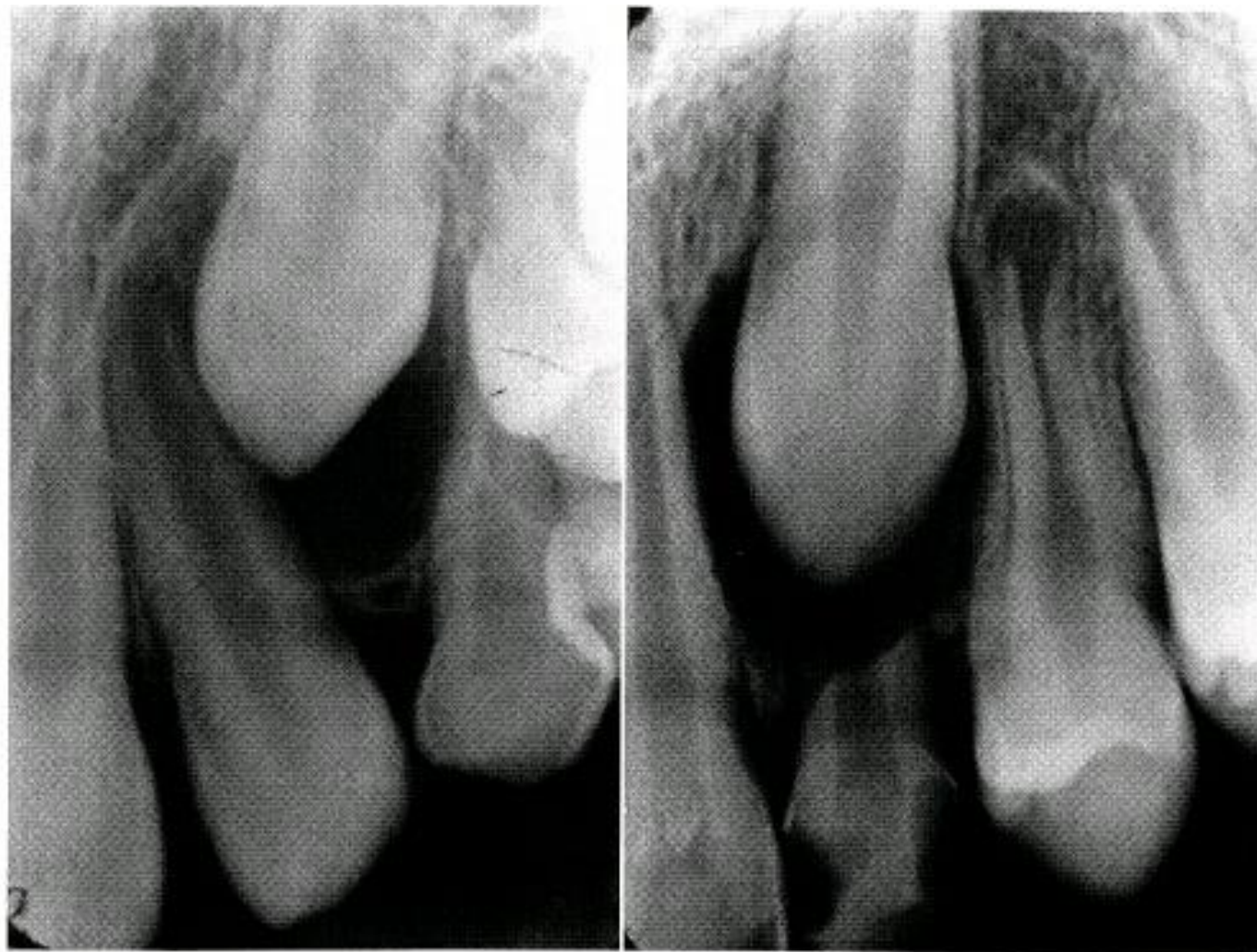

رادیولوژی های پری کرونال

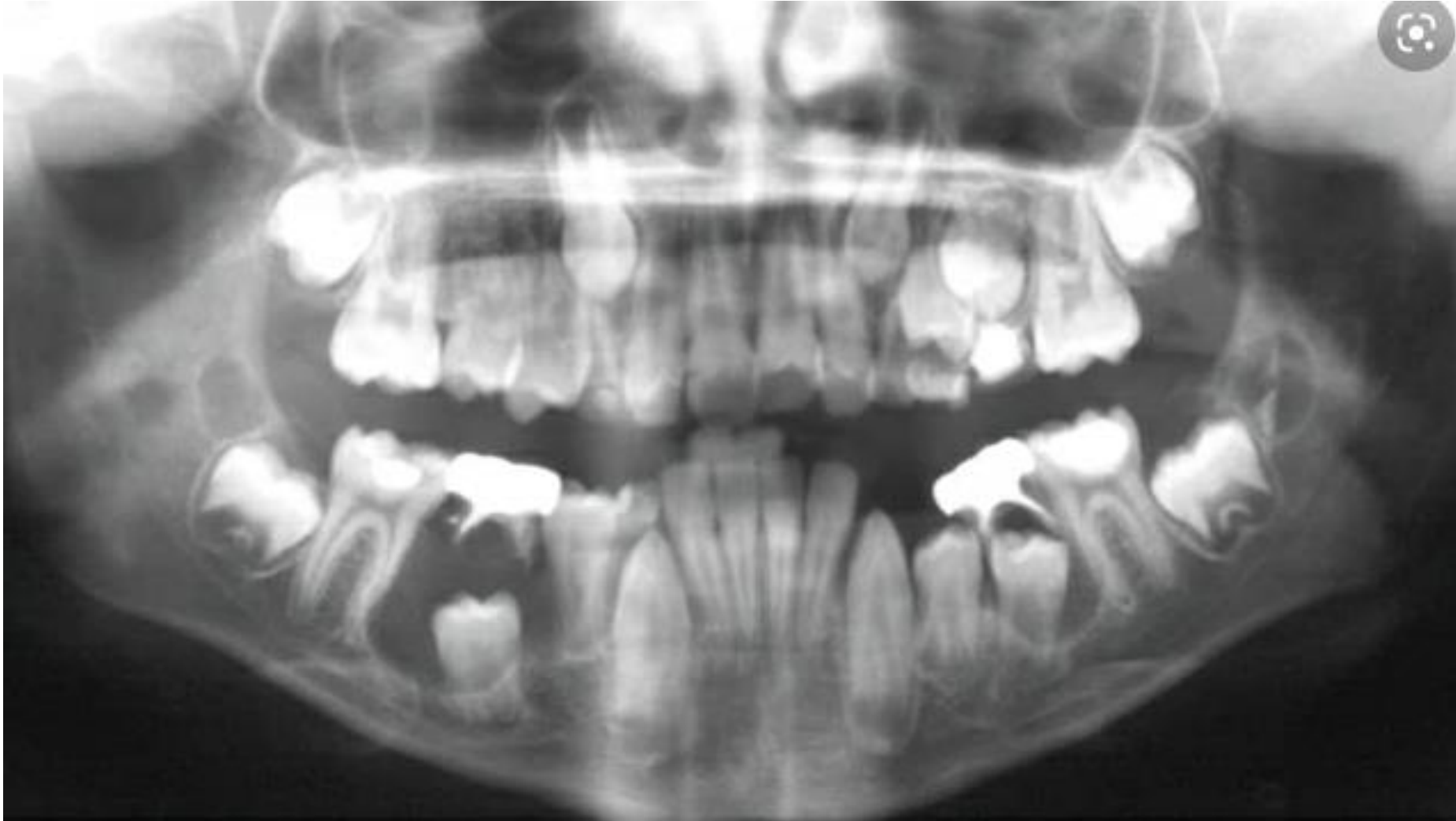فضای فولیکولار نرمال



فضای فولیکولار



کیست دنتی ژروس



راديو لوسنسى جنراليزه



