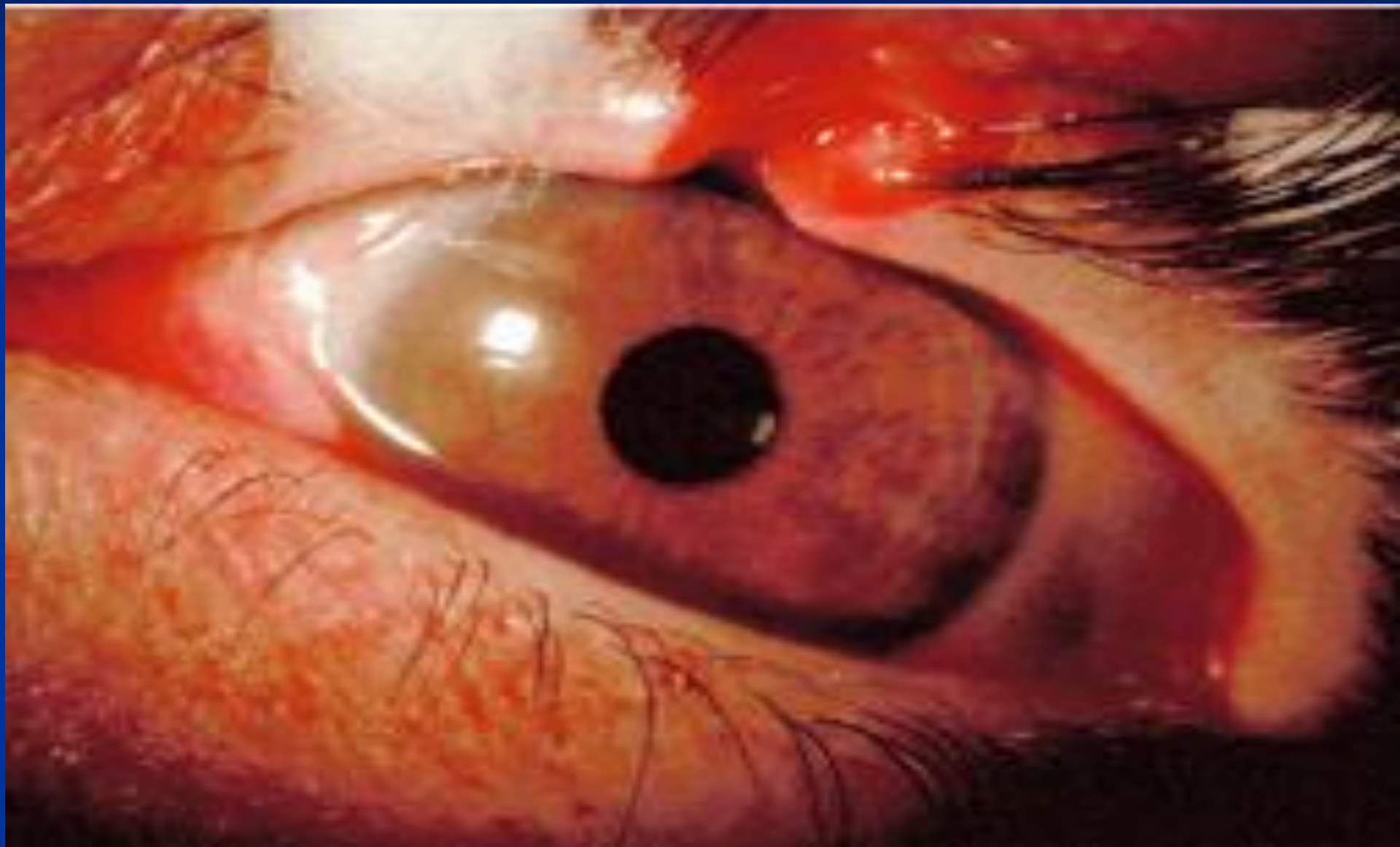

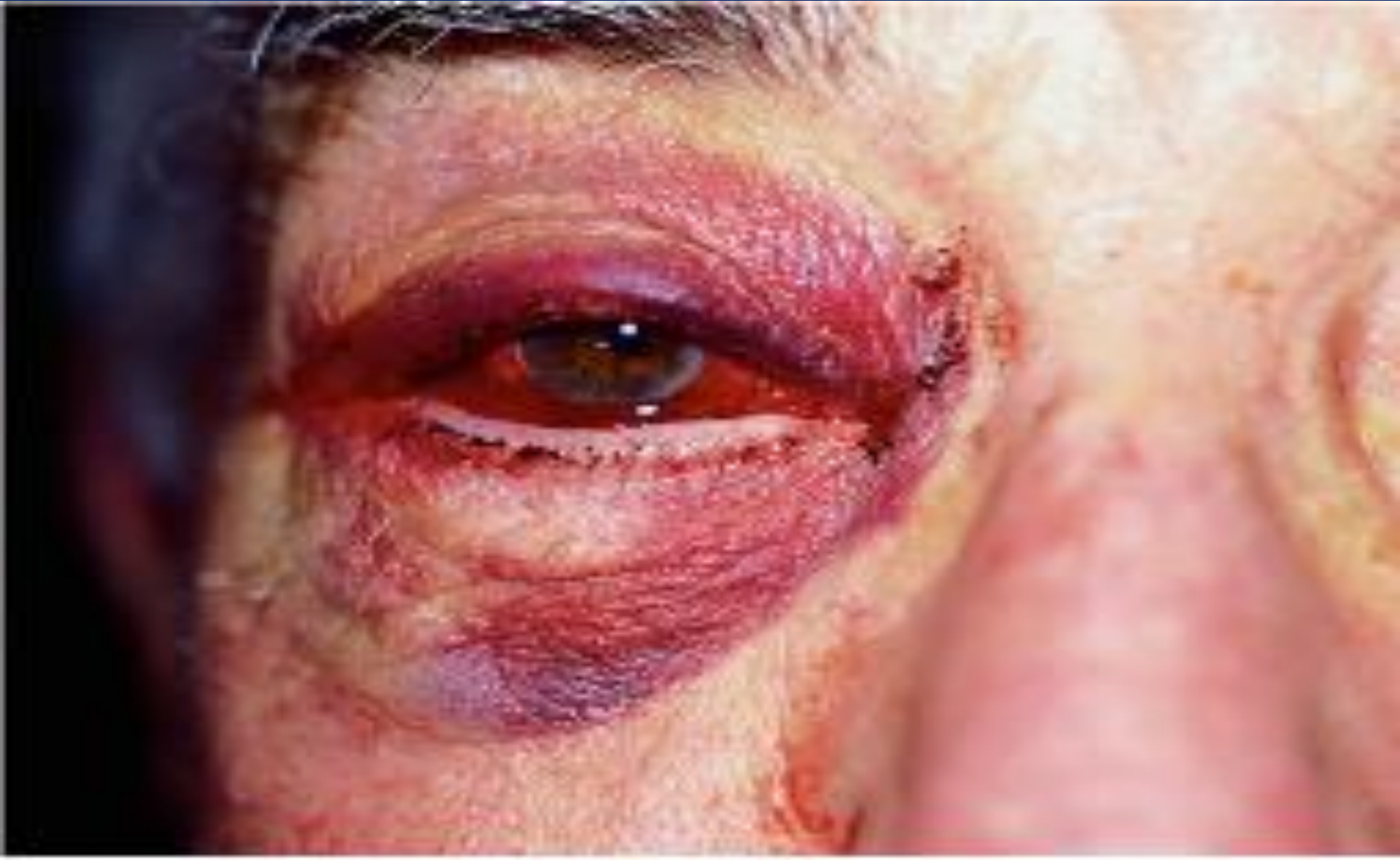EYE TRAUMA

SEYED AHMAD RASOULINEJAD
VITREORETINAL SURGEON

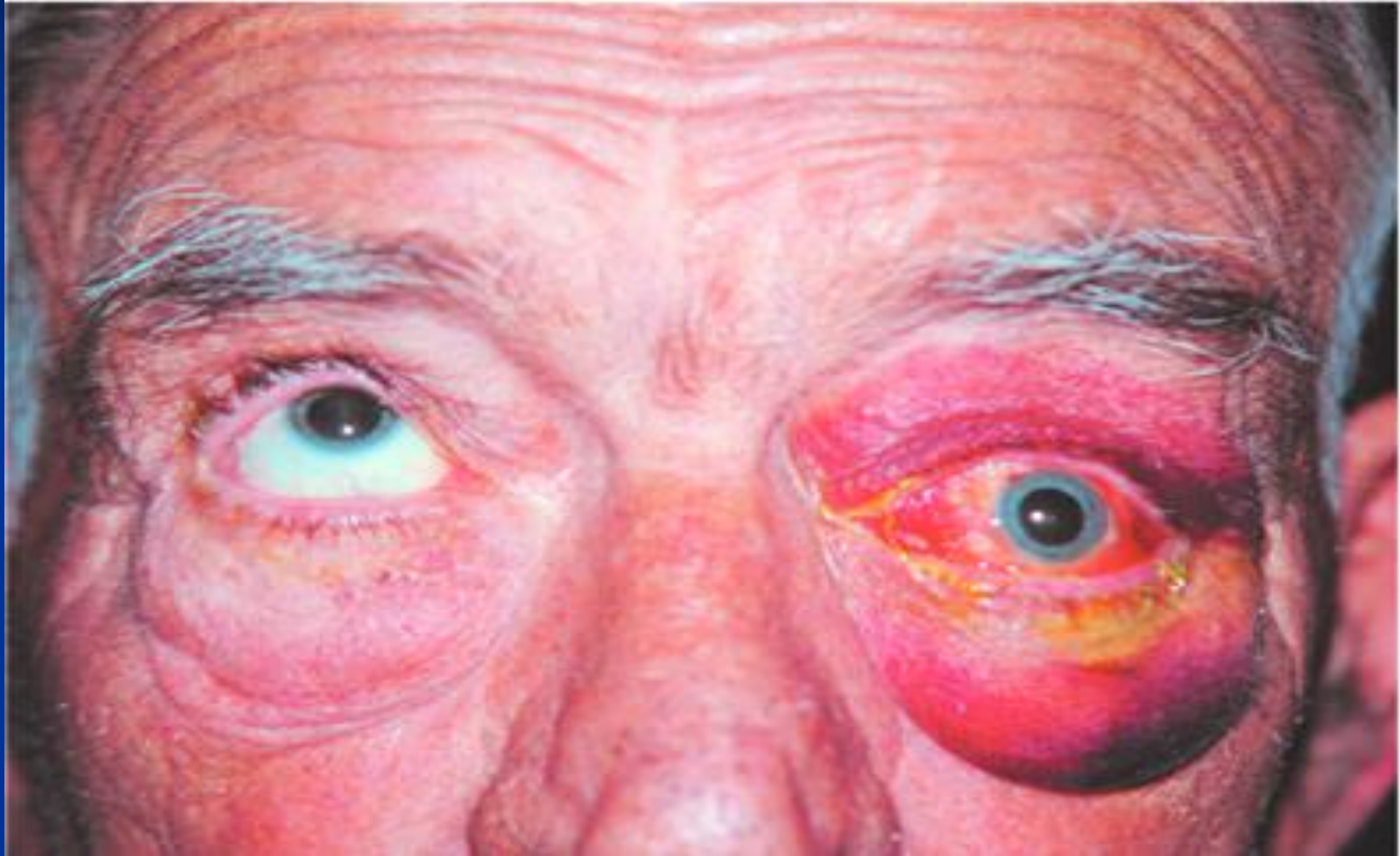Lid Laceration



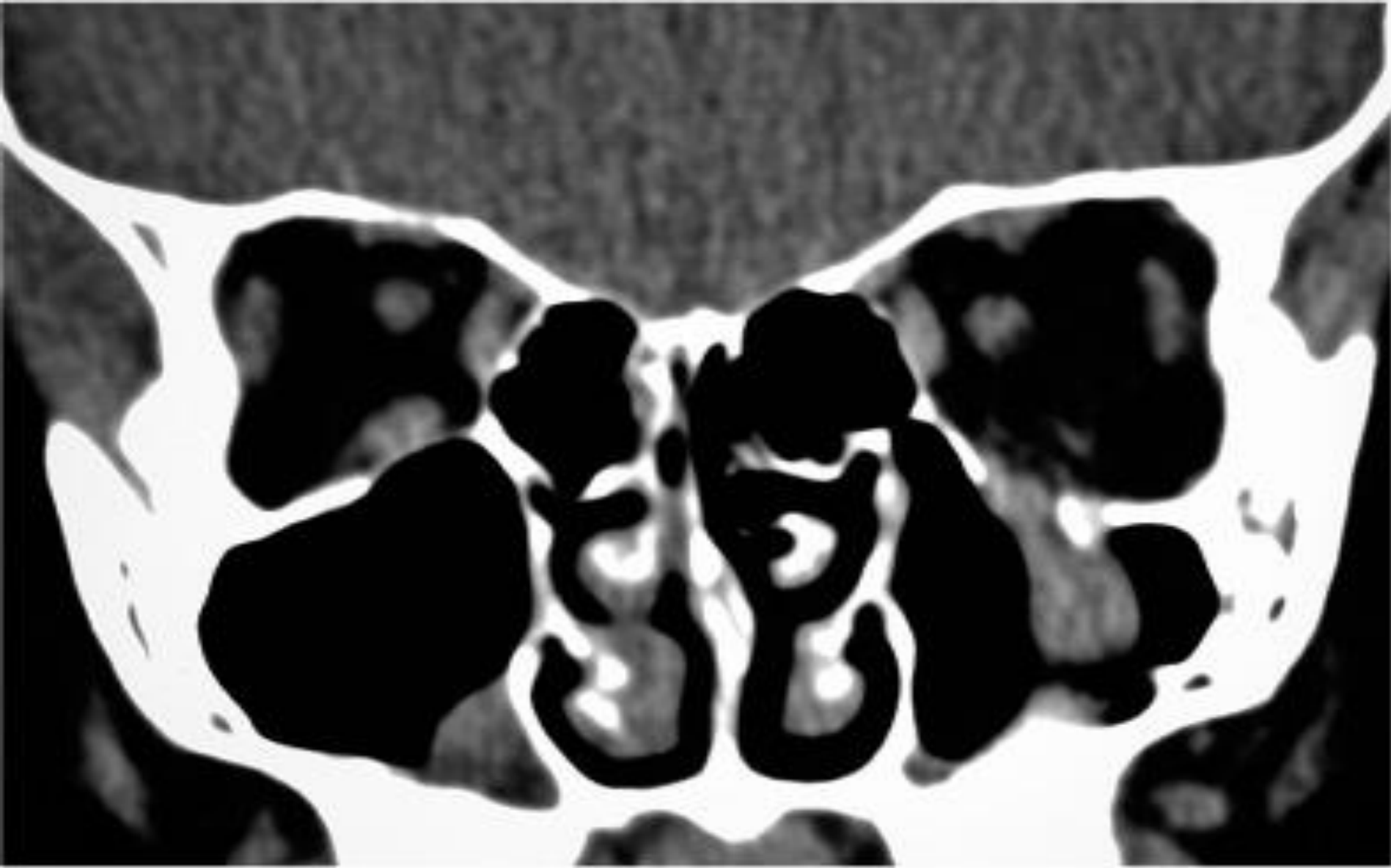
Subconjunctival hemorrhage



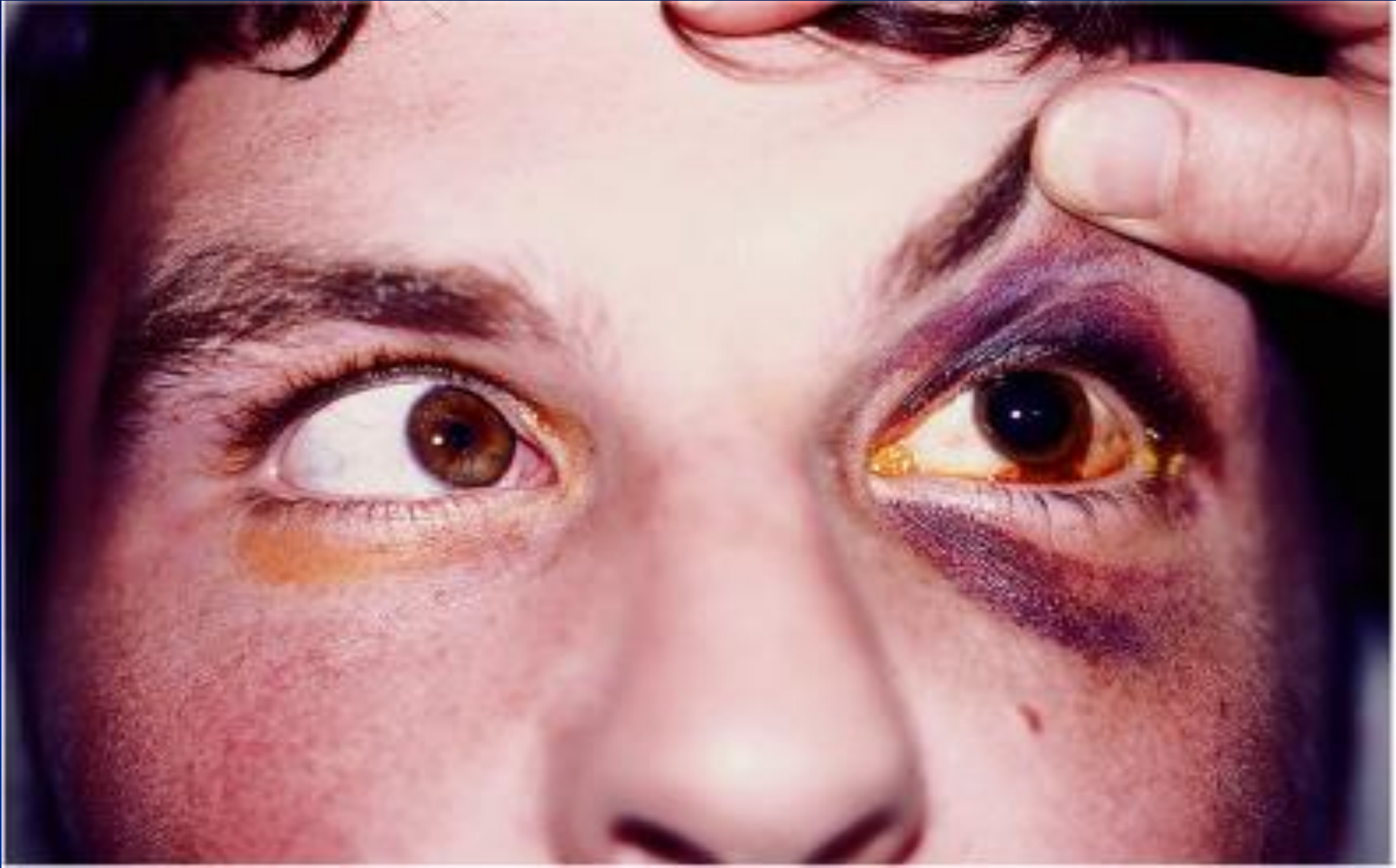*Blow-out Fracture
Limitation of upgaze*



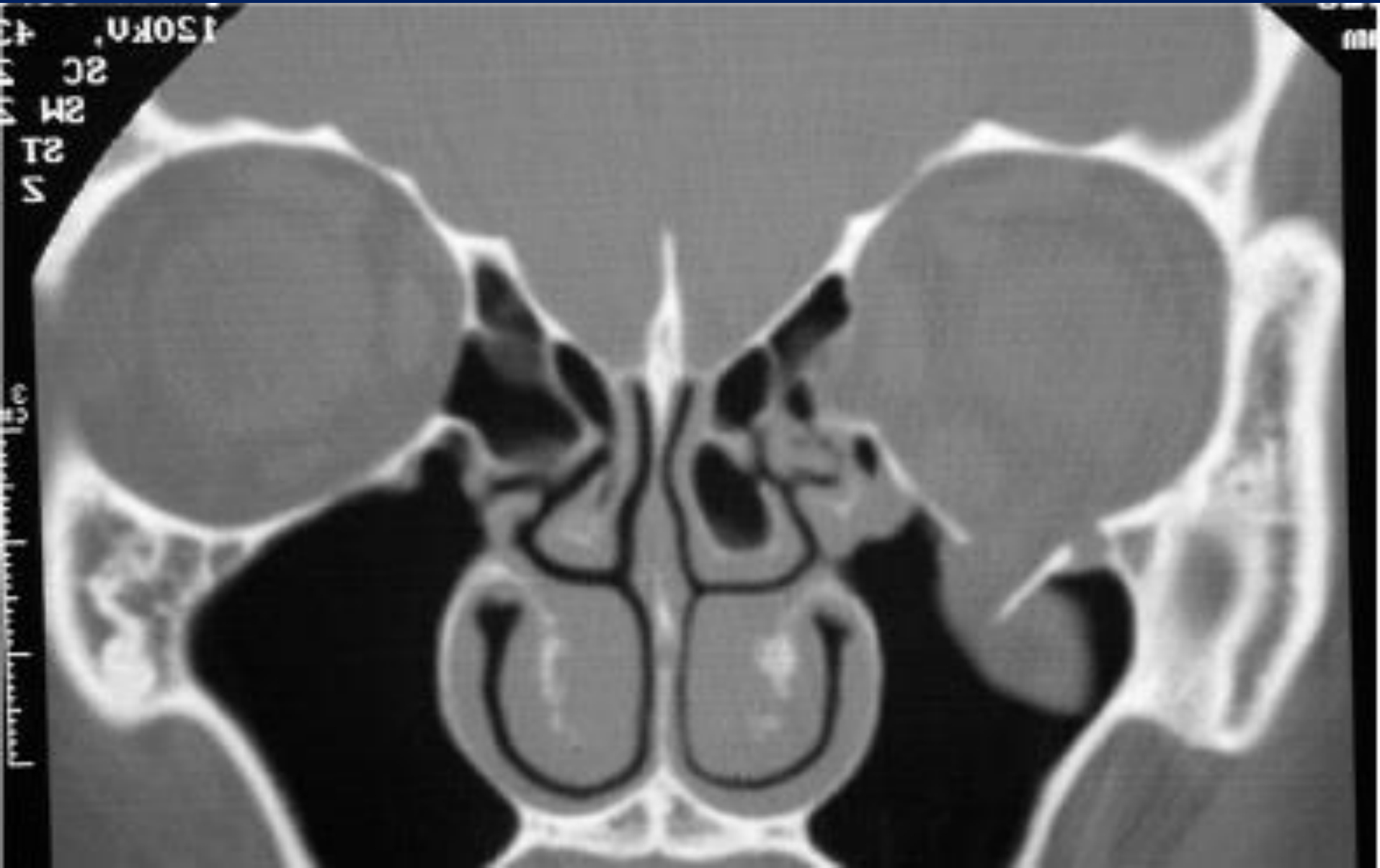
*Blow-out Fracture
Inferior rectus incarceration*



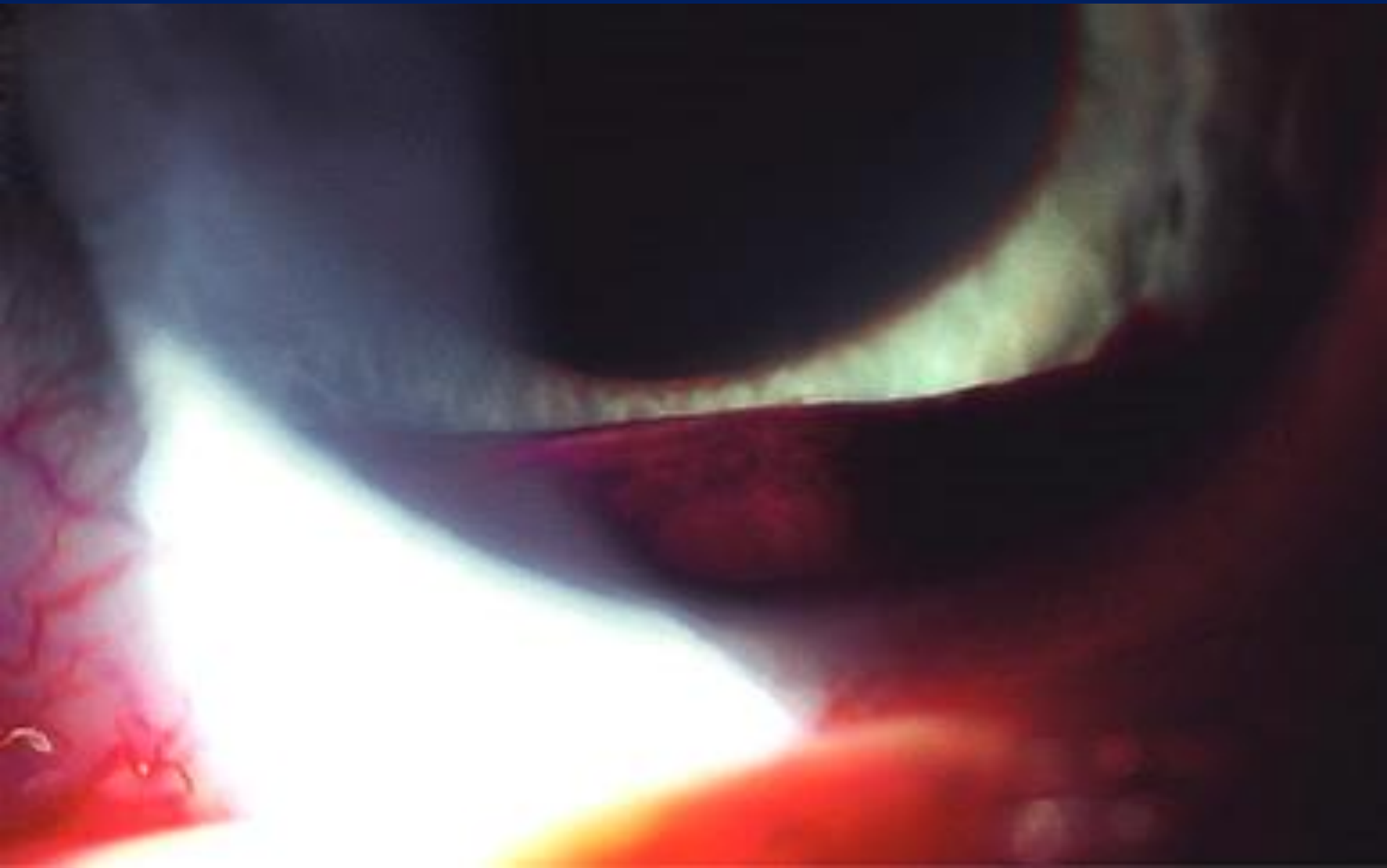
*Blow-out Fracture
Limitation of abduction*



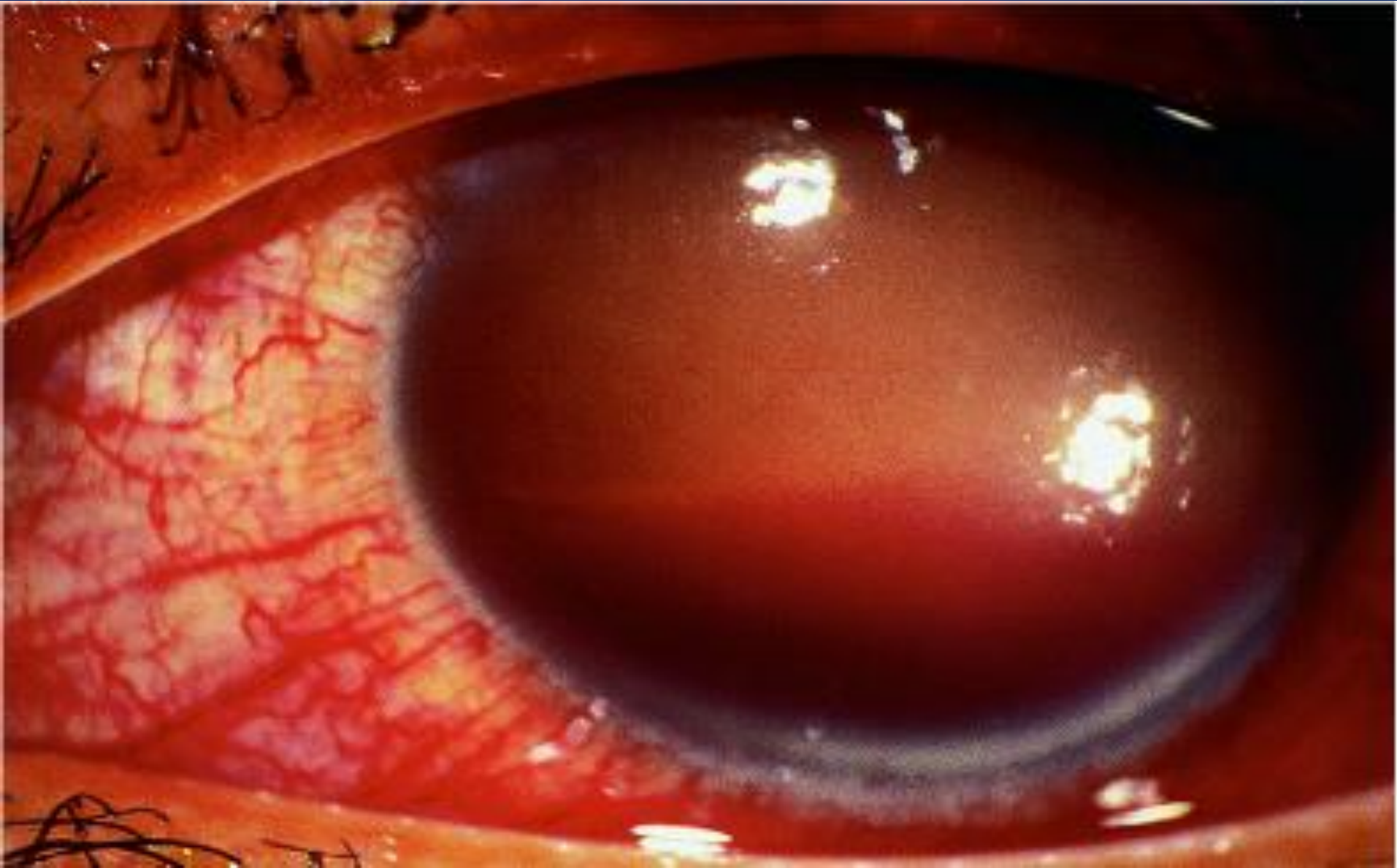
*Blow-out Fracture
Medial rectus incarceration*



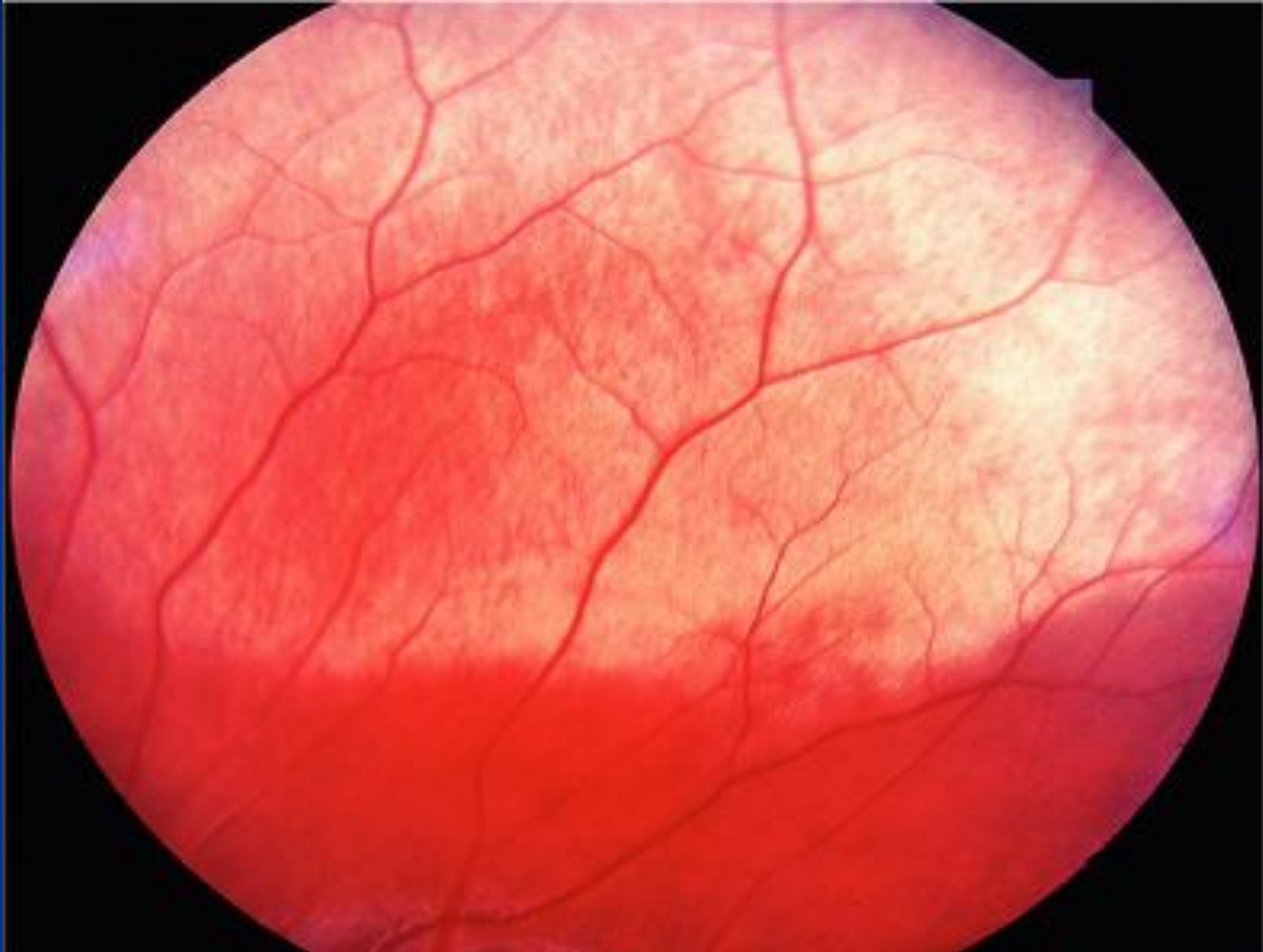Hyphema



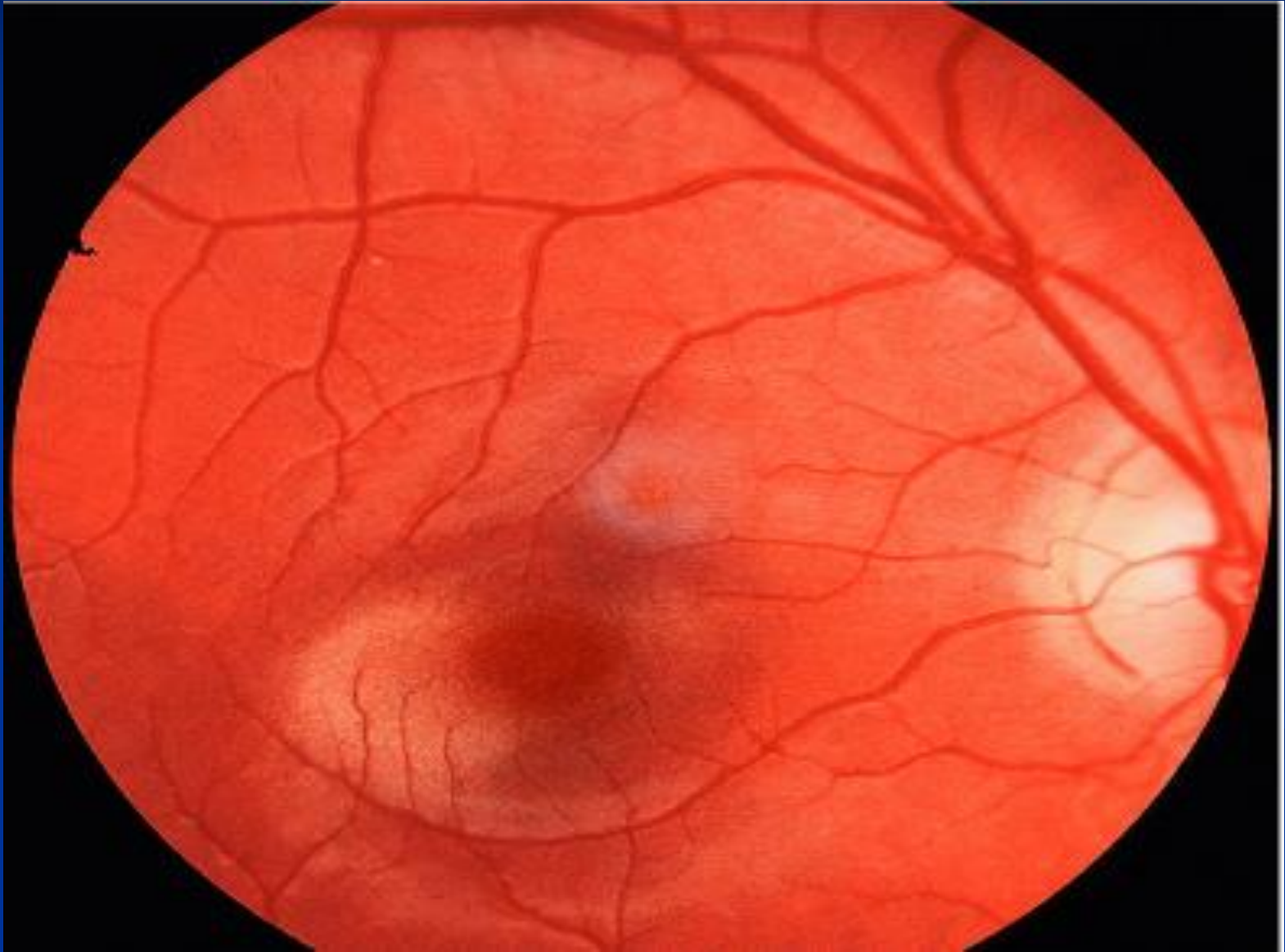Total Hyphema



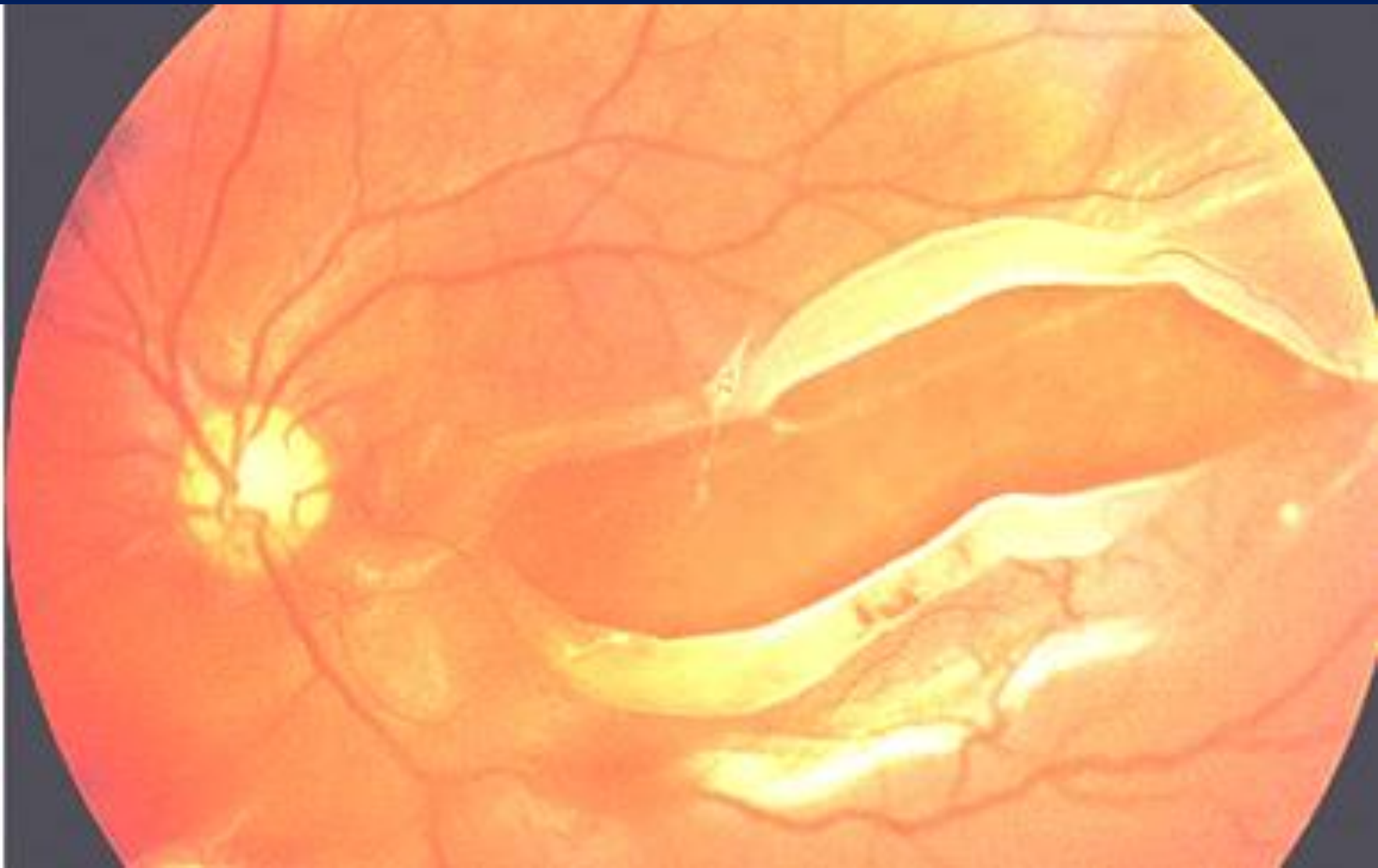
Commotio Retinae



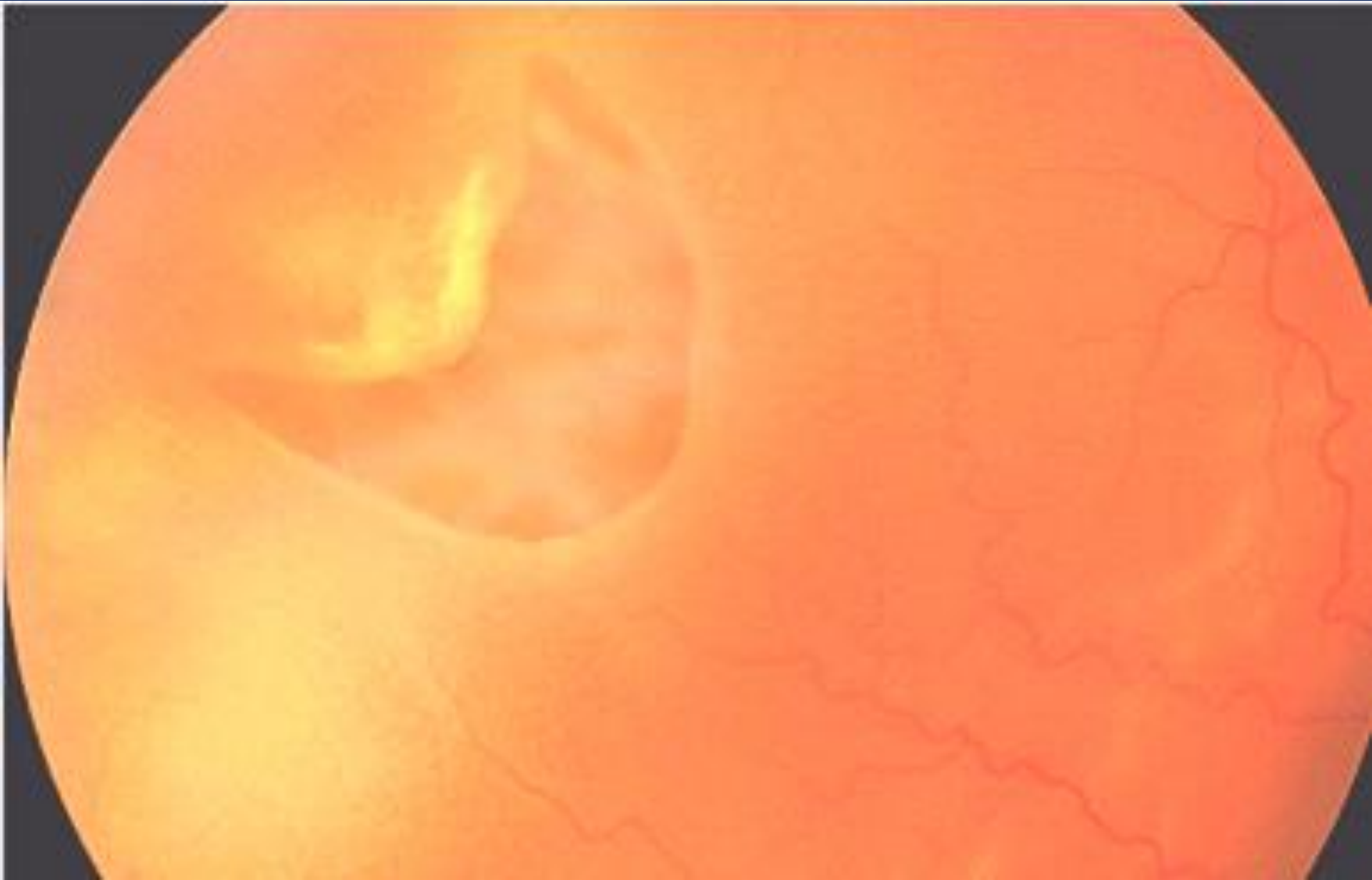
Commotio Retinae



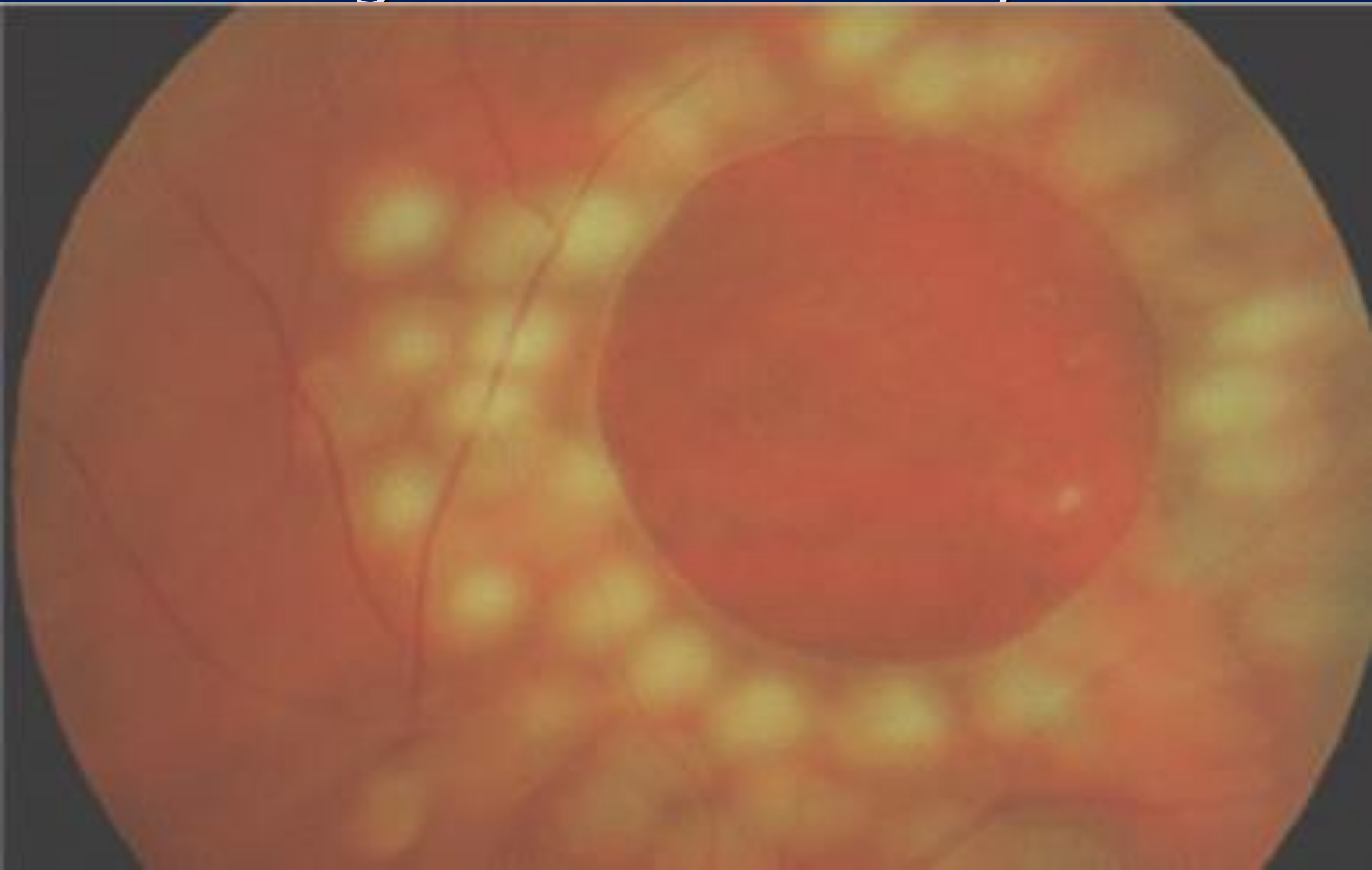Retinal Detachment Giant Tear



*Retinal Detachment
Horseshoe tear*

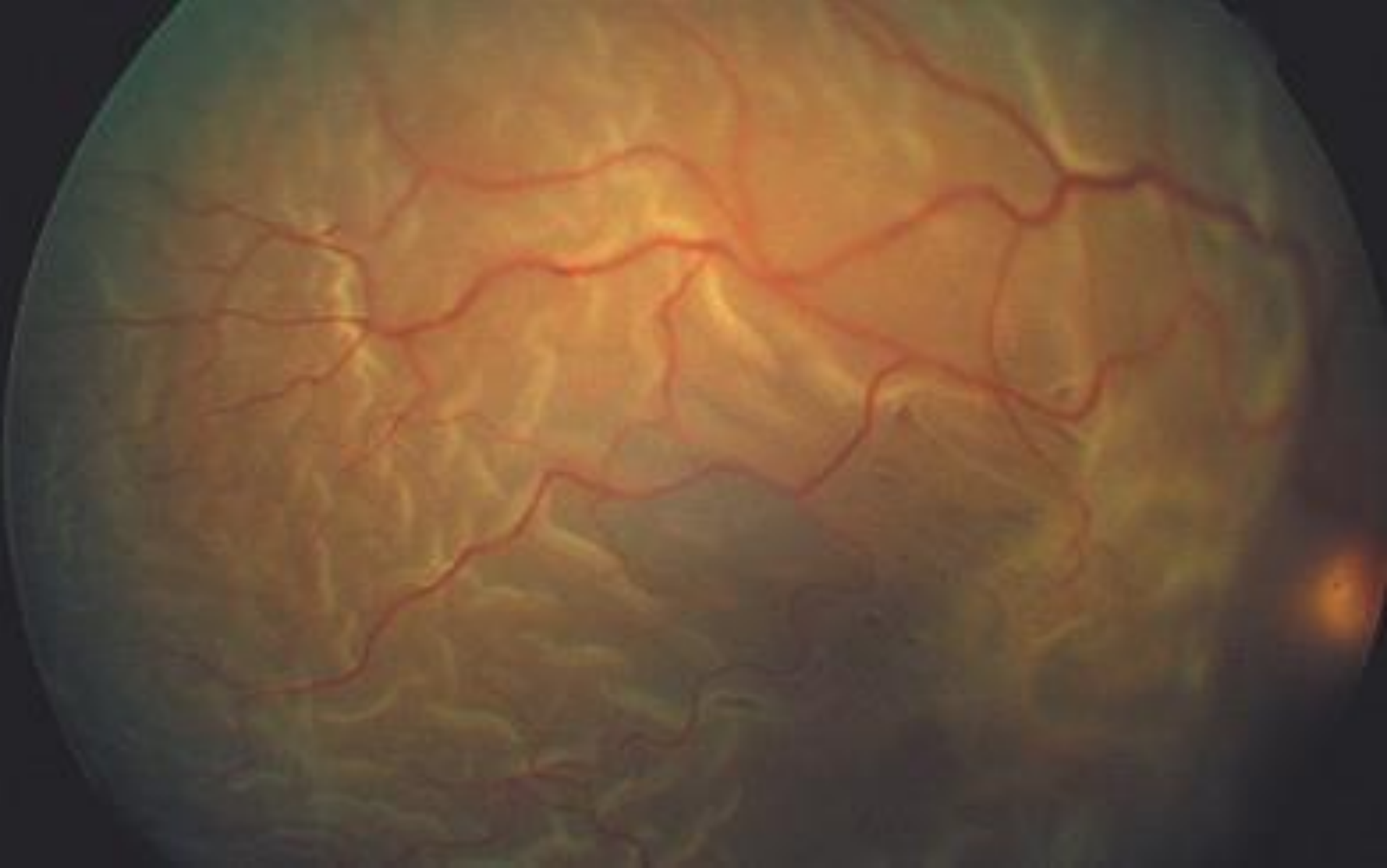


Retinal Detachment
Large hole with laser spots



Retinal Detachment

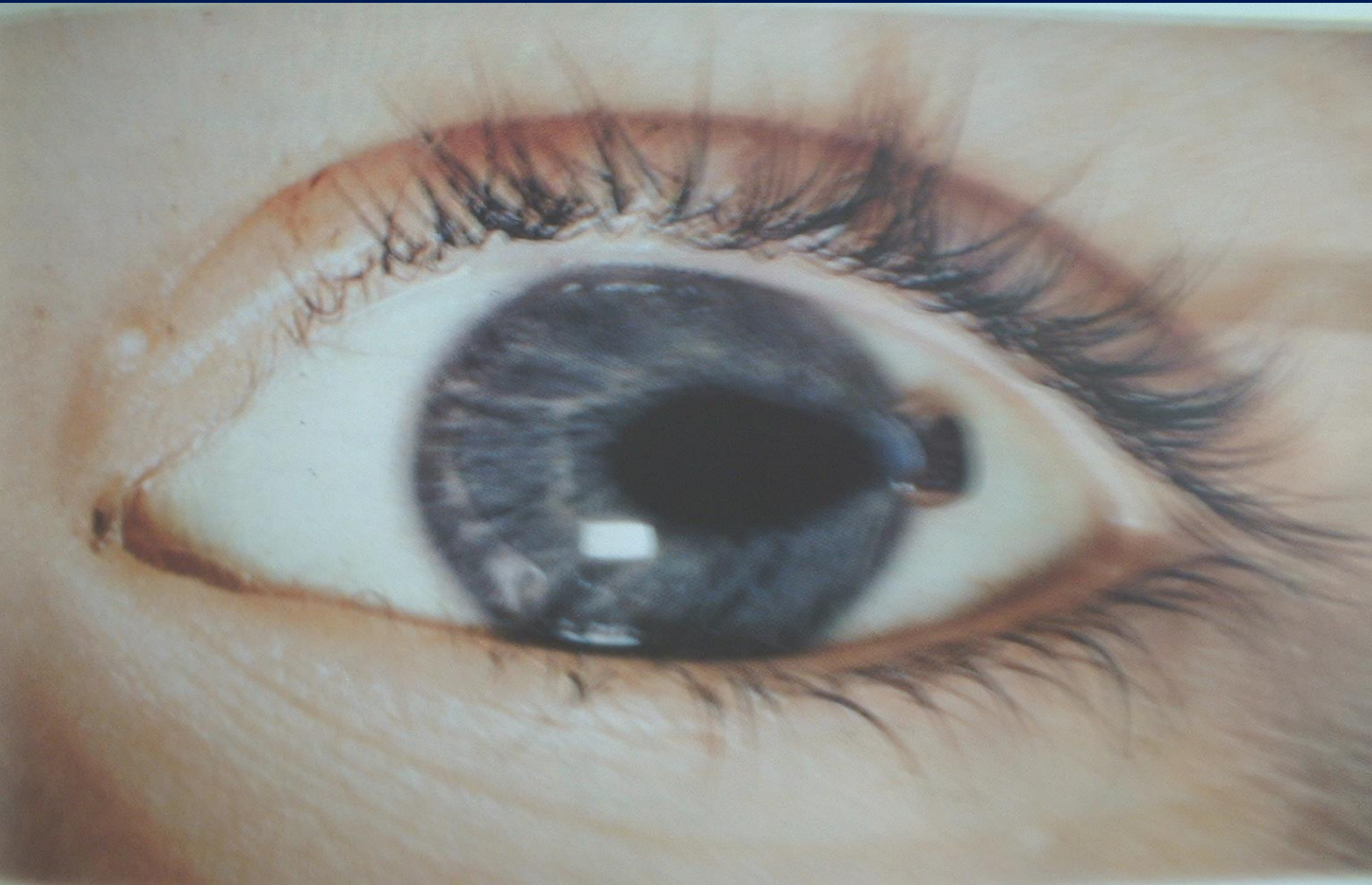Folds and opacification of retina



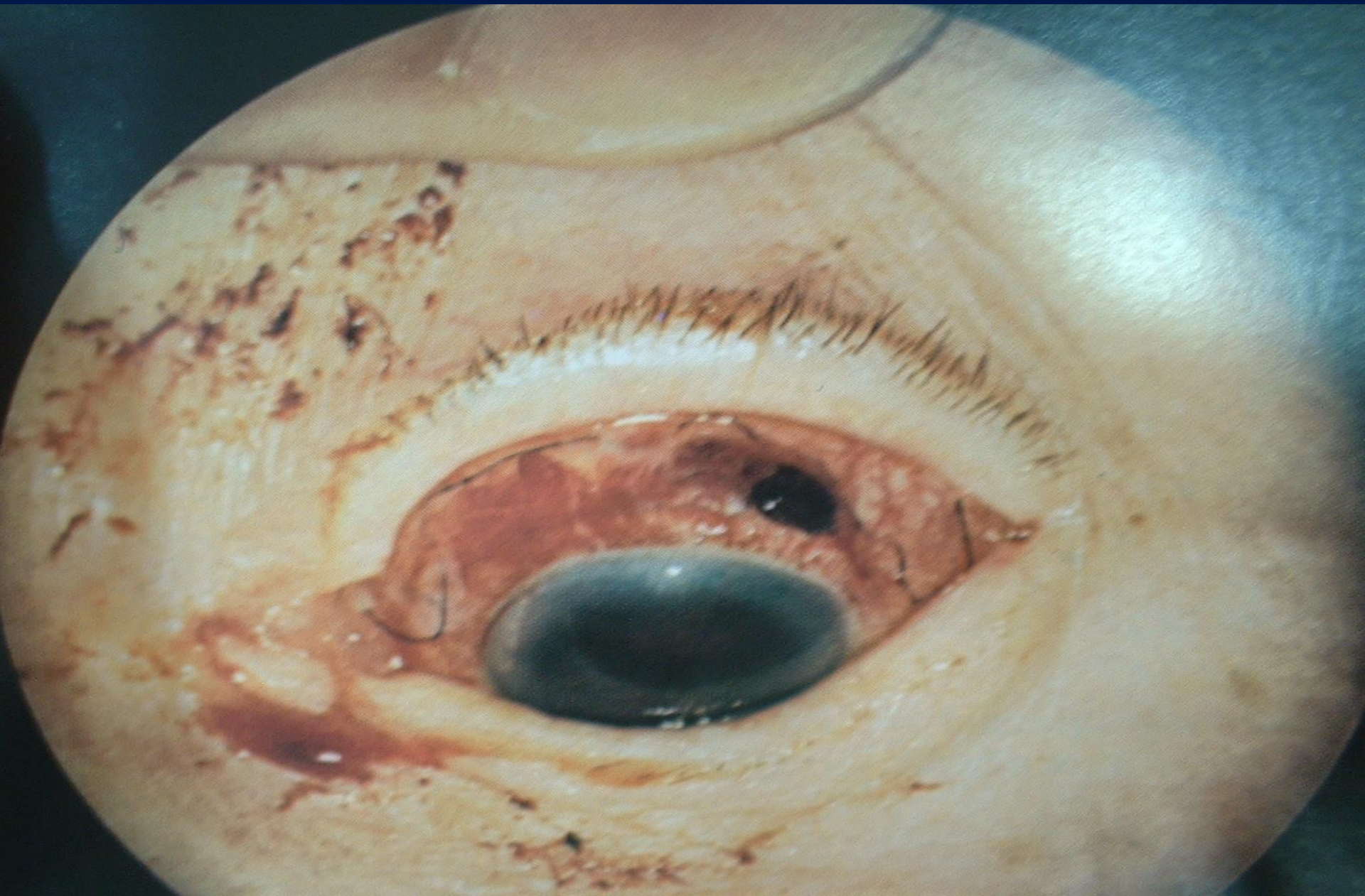
Retinal Detachment
Superior detachment



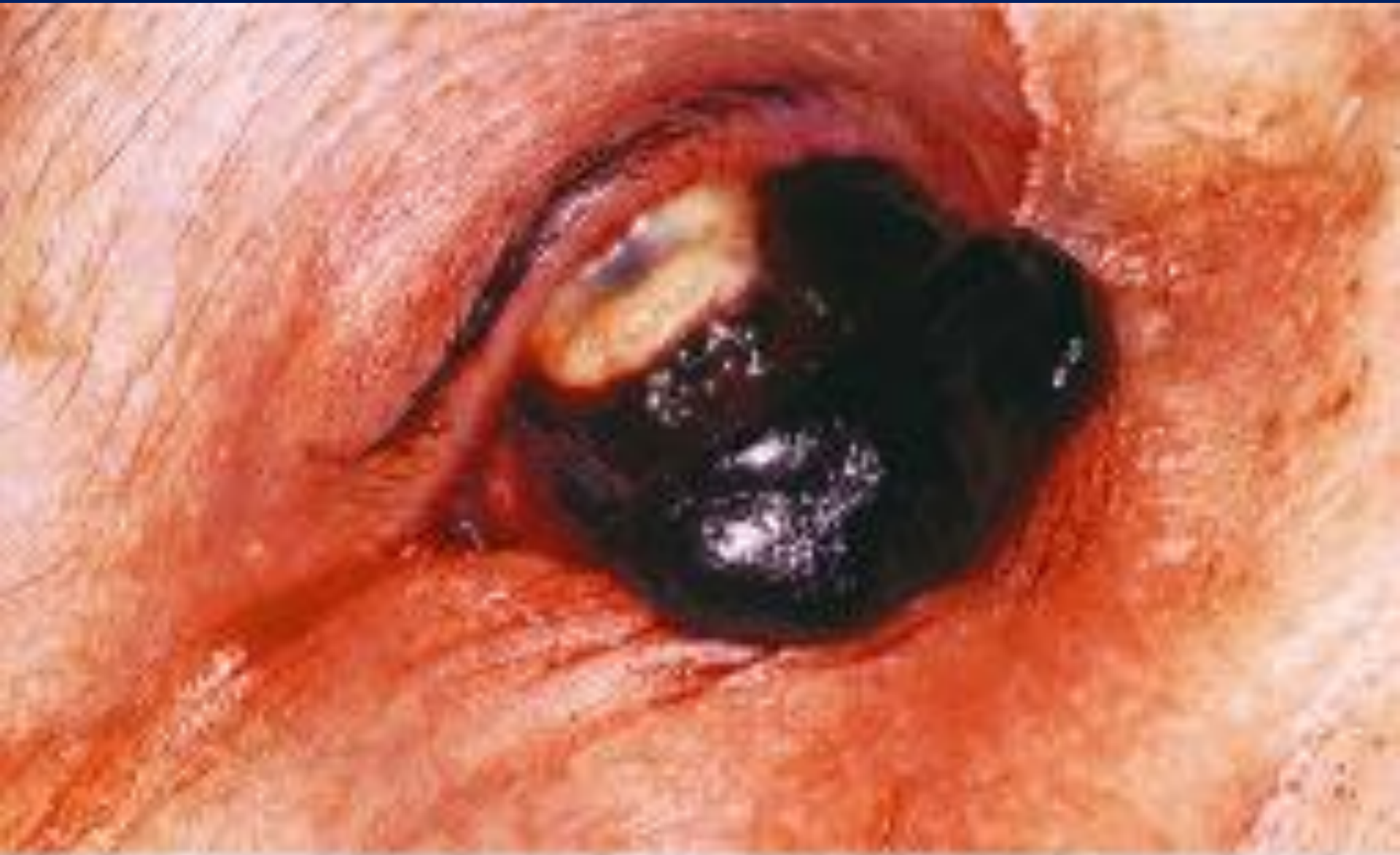Corneal Laceration



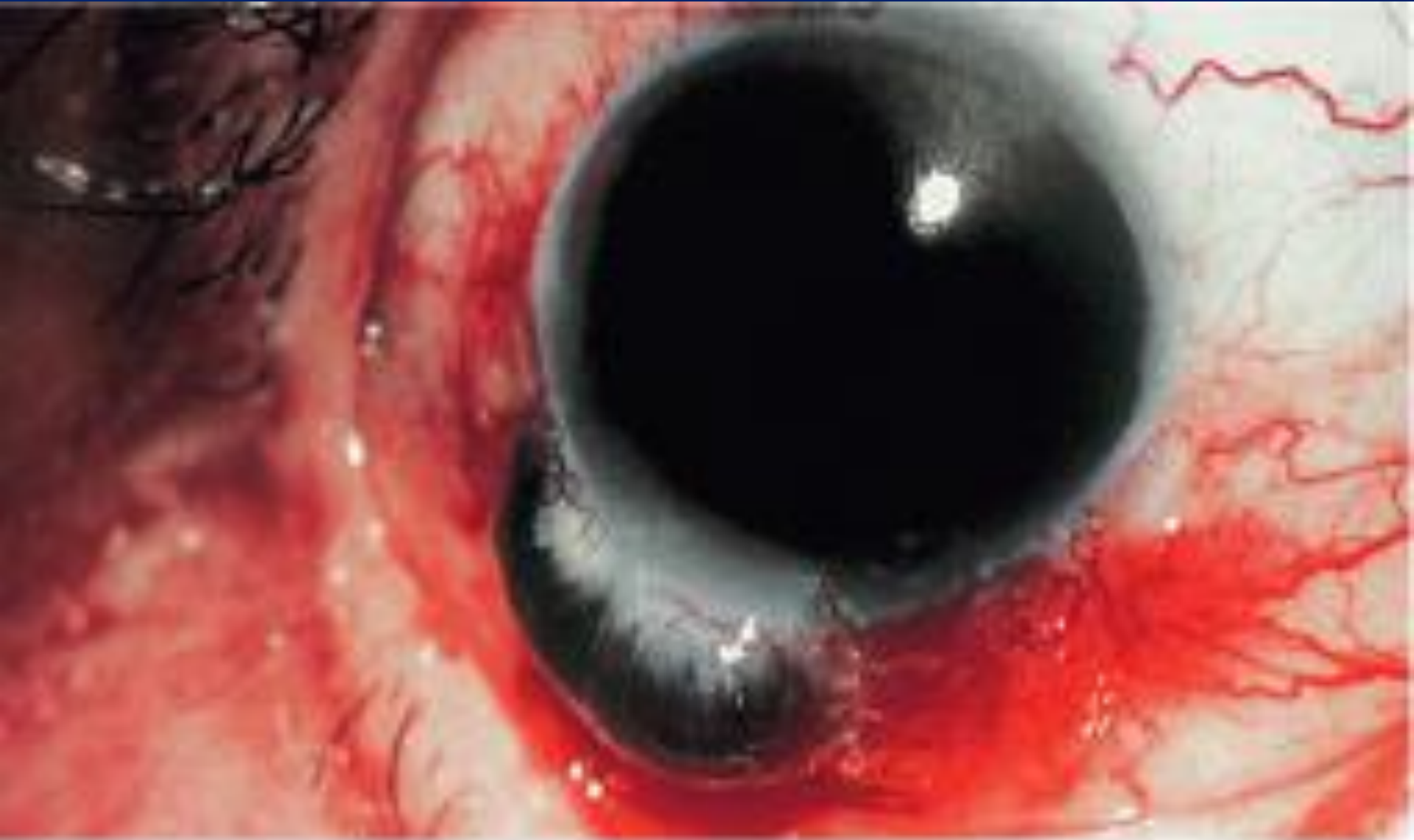Scleral Laceration



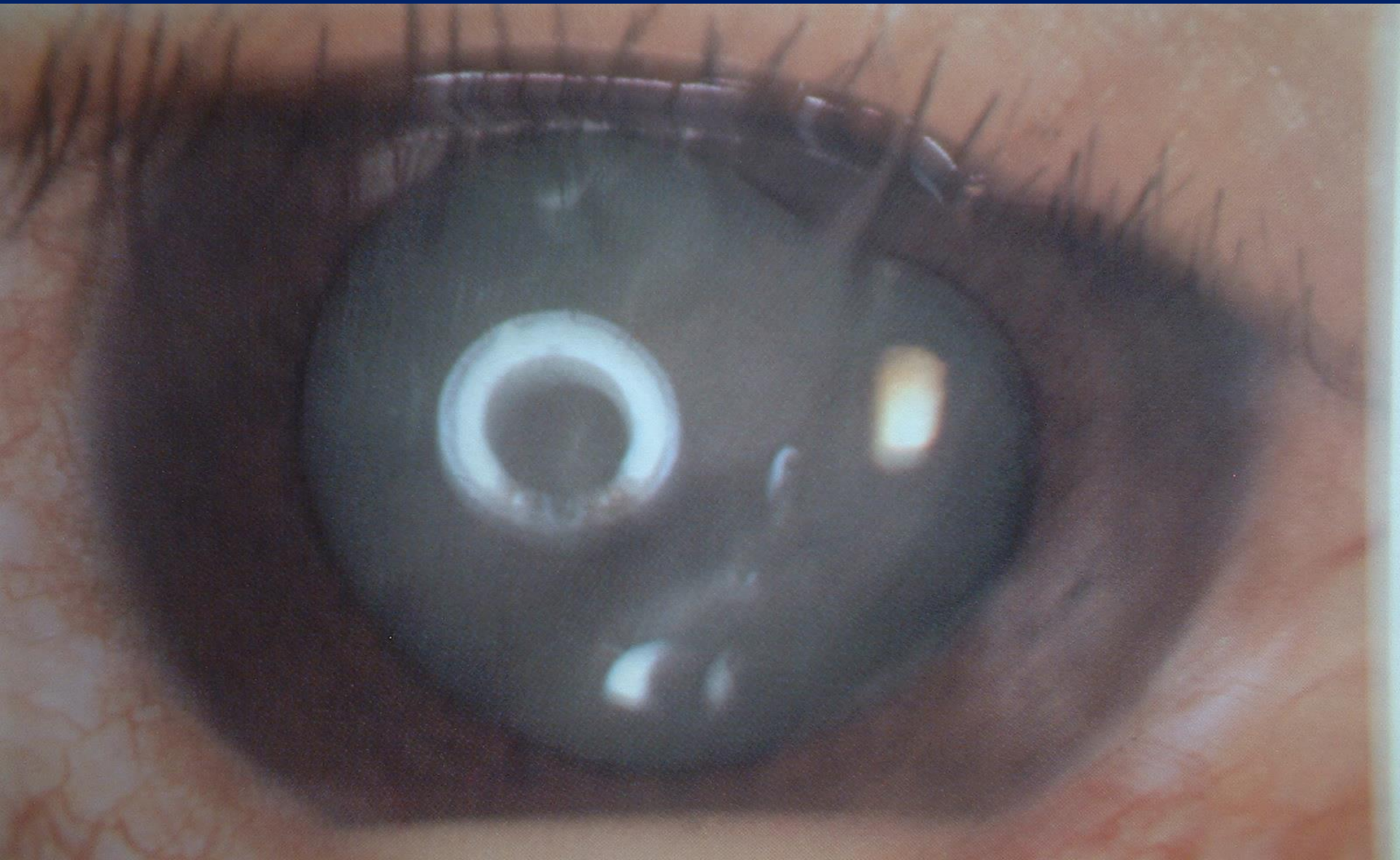
Rupture Globe



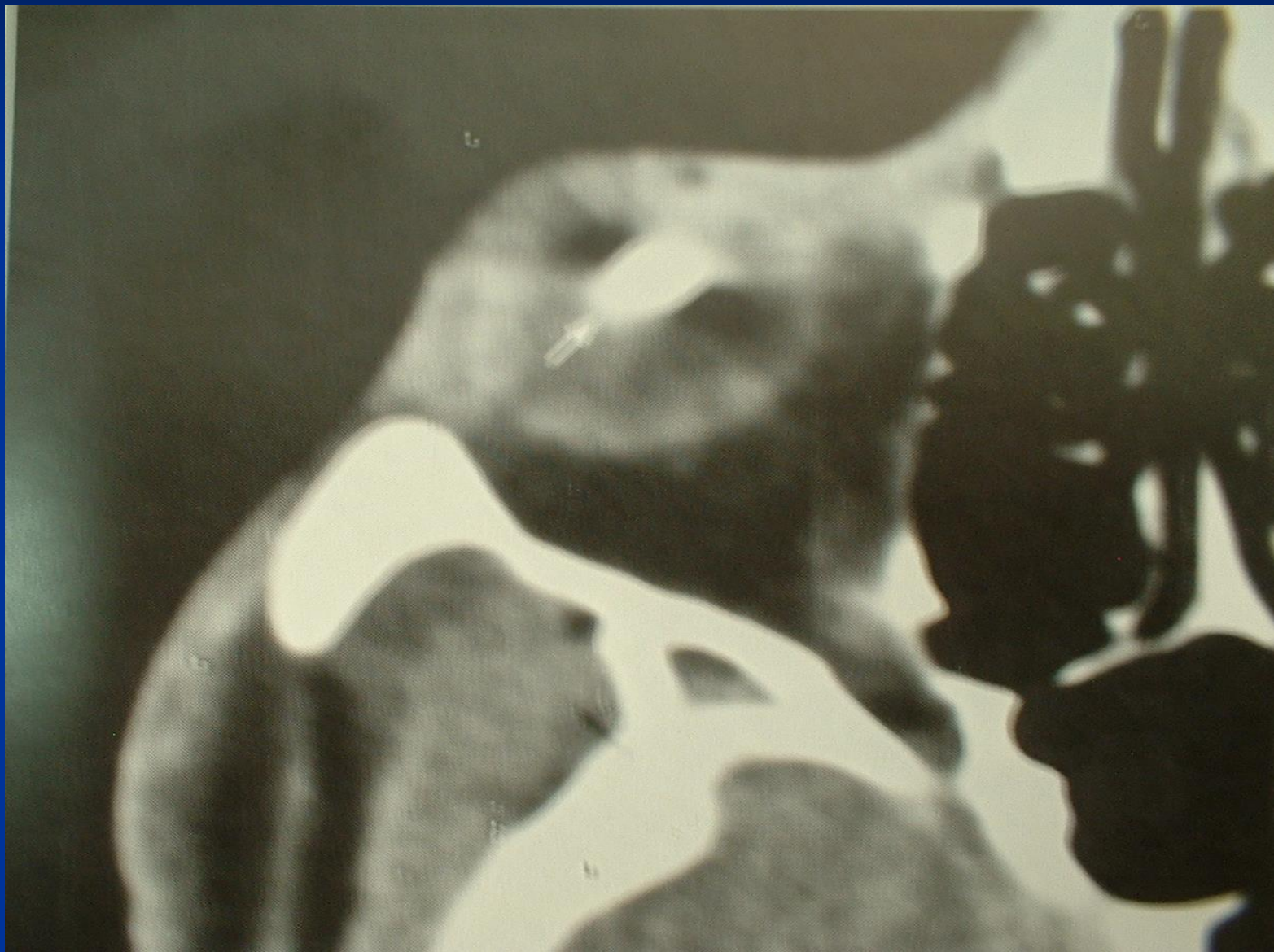Total Hyphema and iris prolapse



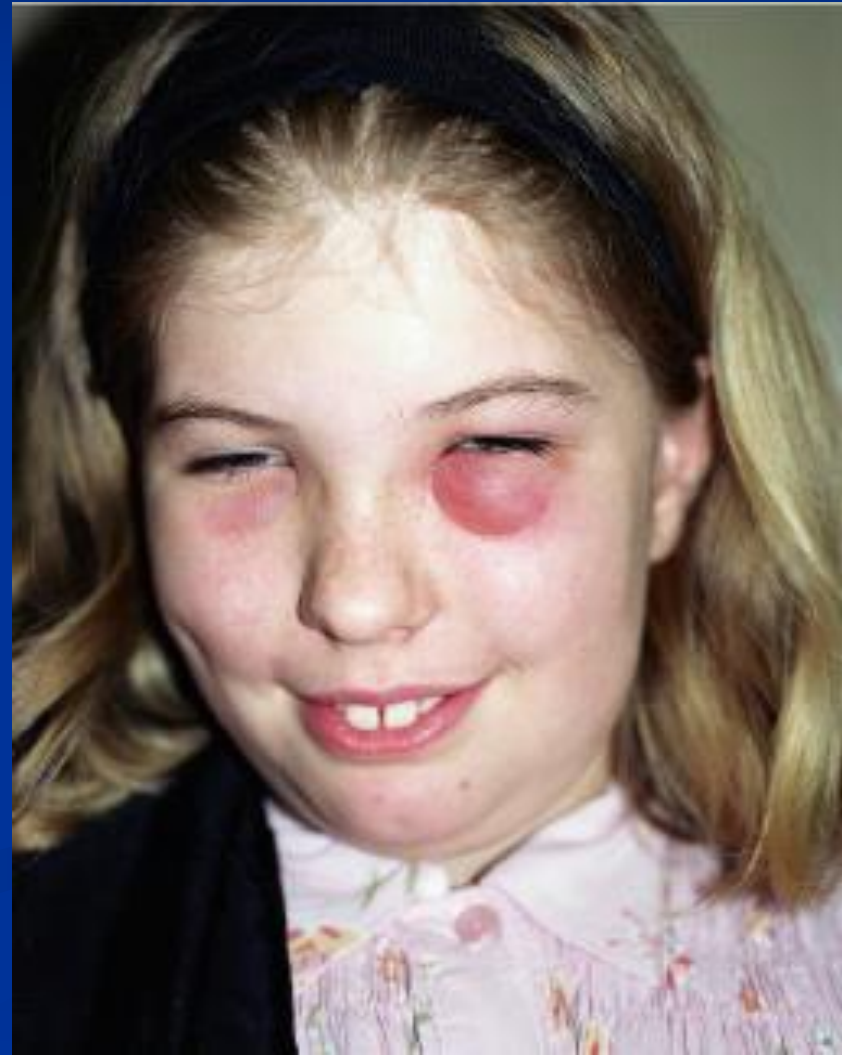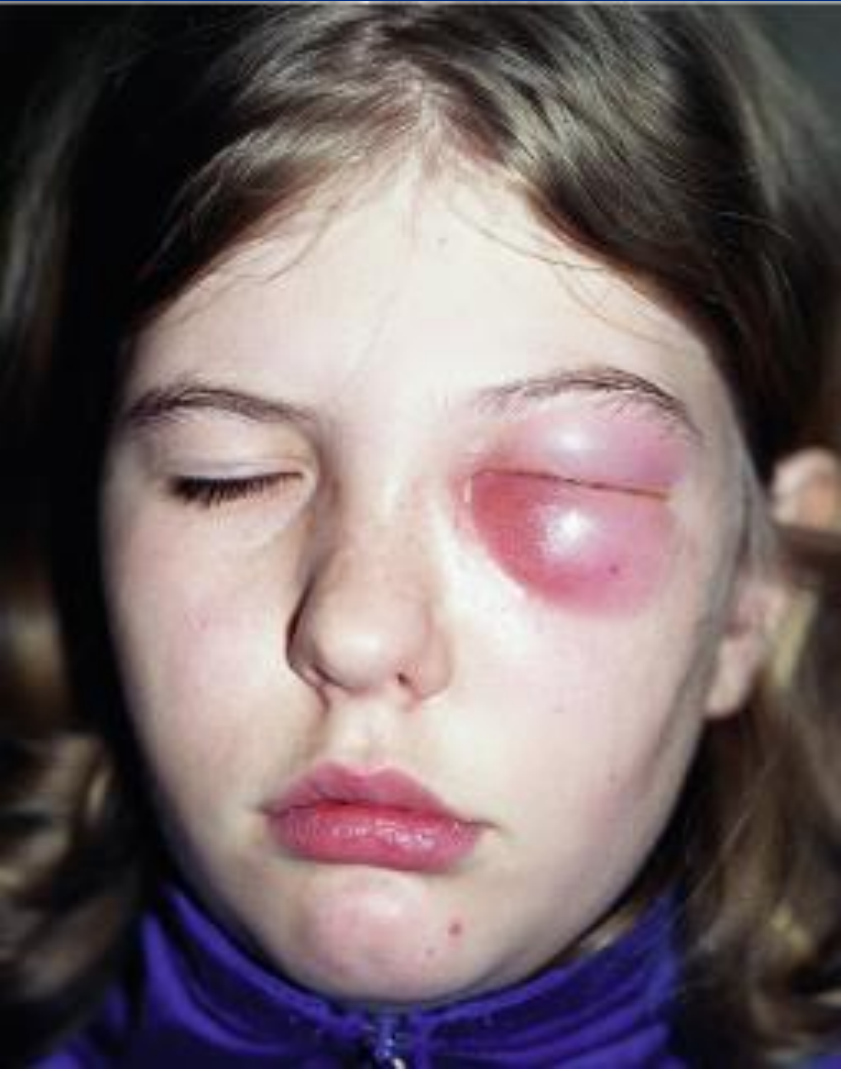Traumatic cataract with IOFB



Traumatic cataract with IOFB

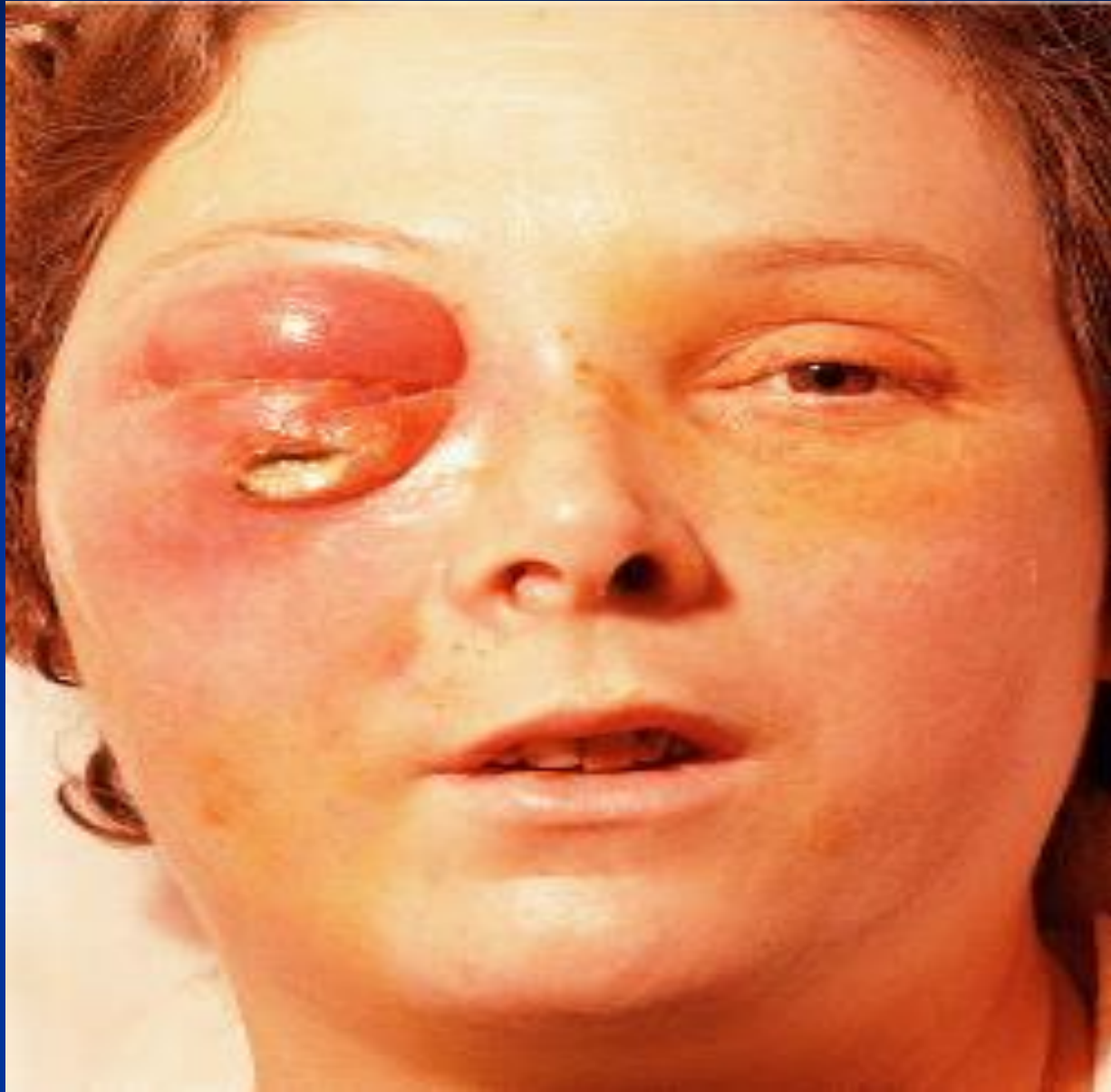

Orbital cellulitis in children usually with ethmoiditis

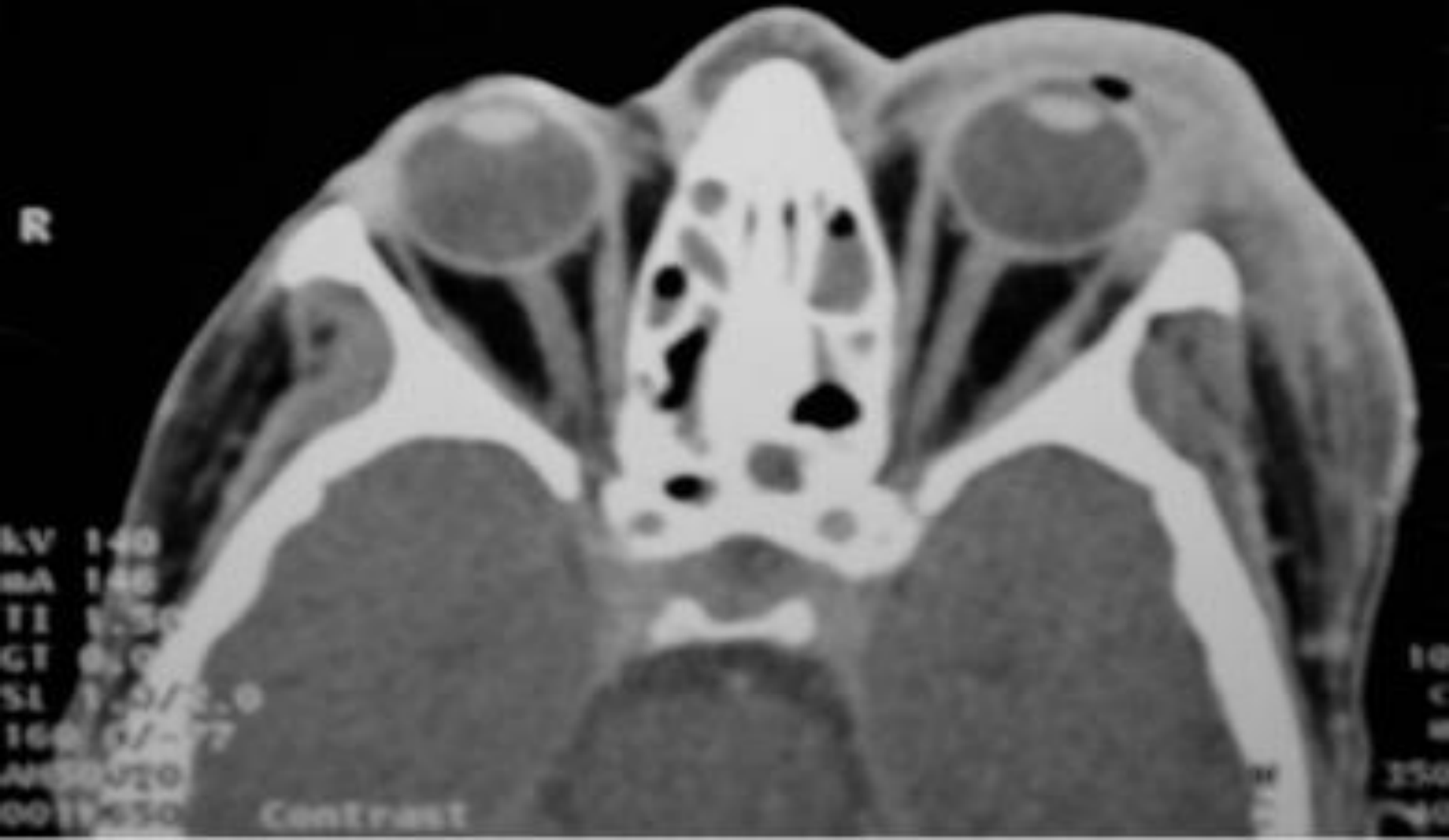

Orbital cellulitis

Post Traumatic Abscess formation



*Preseptal cellulitis
Opacification anterior to septum*



Orbital cellulitis

Involvement of orbit



